Other Topical Medications 129

Mark Marchitto, Matthew Fox, Yolanda R. Helfrich and Sewon Kang

Chapter Contents

General Principles of Topical Therapy 2295
Antipruritic Agents 2296
Keratolytics and Humectants 2296
Skin-Lightening Agents 2297
Agents that Affect Hair Growth. 2298
Immunomodulatory Agents 2300
Chemotherapeutic Agents 2303
Vitamin D Analogues 2304
Miscellaneous Agents. 2305

Key features

- Absorption of topical medications depends upon several factors, including cutaneous barrier function, the anatomic site, the active agent, and characteristics of the vehicle
- In neonates, there is a greater risk of systemic toxicity with use of topical medications
- Combination or rotational therapy using topical agents may result in increased efficacy and decreased risk of side effects

INTRODUCTION

Topical medications are fundamental in the armamentarium of dermatologic therapeutics, offering the ability to deliver treatment directly to the skin while limiting systemic side effects. However, topical therapy can be time-consuming and messy, and it may not be practical for generalized skin disorders or effective for conditions with deeper involvement. Choosing an appropriate topical regimen requires consideration of the disease process and involved site(s) as well as the vehicle, application strategy, and duration of use of the selected agent. This chapter reviews general principles of topical therapy and topical medications not discussed elsewhere in the textbook. Table 129.1 lists topical medications covered in other chapters.

GENERAL PRINCIPLES OF TOPICAL THERAPY

Topical formulations consist of an active ingredient in a non-active base (vehicle). To be effective, topical medications must gain entry into the skin and reach the desired target site, e.g. the epidermis below the stratum corneum or the dermis, in adequate concentrations. Successful topical therapy therefore requires percutaneous absorption, which depends upon factors related to the skin being treated as well as the agent and its vehicle (Table 129.2). The role of the stratum corneum in skin barrier function, including percutaneous absorption of medications, is discussed in Chapter 124.

Quantity of Application

In general, topical medications should be applied to the skin as a thin layer. A thicker layer of medication does not result in enhanced penetration or additional therapeutic benefit. One gram of cream covers a ~10 cm × 10 cm area of skin, and the same amount of ointment spreads nearly 10% further.

TOPICAL MEDICATIONS DISCUSSED IN OTHER CHAPTERS	
Topical medications	**Chapter(s)**
Chapters on medical therapy or cosmetics	
Glucocorticoids	125
Retinoids	126
Antimicrobials (antibacterials, antifungals, antivirals)	127
Sunscreens	132
Anesthetics	143
Cosmeceuticals	153
Chemical peel agents	154
Other chapters	
Clascoterone for acne	36
Brimonidine and oxymetazoline for facial erythema in rosacea	37
Aluminum chloride and topical anticholinergic agents for hyperhidrosis	39
Topical immunotherapy for alopecia areata (with squaric acid dibutyl ester or diphencyprone)	69
Sinecatechins for anogenital warts	79
Antiparasitic agents (including treatments for infestations)	83, 84
Insect repellents	85
Topical β-blockers (e.g. timolol) for infantile hemangiomas	103
Wound healing agents	105, 141
Tirbanibulin for actinic keratoses	109
Hemostatic agents	151

Table 129.1 Topical medications discussed in other chapters.

FACTORS THAT AFFECT PERCUTANEOUS ABSORPTION
Characteristics of the patient/skin

• Patient age
  • Suboptimal skin barrier function in neonates, especially if premature (see Table 129.4)
• Diseases, physical injuries, or chemical exposures that disrupt skin barrier function (e.g. Netherton syndrome)
• A thicker stratum corneum decreases absorption
• Skin hydration and/or occlusion increase absorption (e.g. in a skin fold)
• Anatomic location (approximate ratio of absorption compared to the forearm)
  • *Higher absorption:* scrotum (40), face (10), axilla (4), scalp (3)
  • *Intermediate absorption*: trunk (1.5), arm (1)
  • *Lower absorption*: palm (0.8), ankle (0.4), sole (0.1)

Properties of the medication/its application

• Drug/prodrug properties that increase absorption
  • Smaller molecular size and/or lower frictional coefficient
  • Increased lipophilicity
  • Increased concentration and/or solubility
• Vehicle composition
• Application under occlusion increases absorption (e.g. ointment, occlusive dressing)

Table 129.2 Factors that affect percutaneous absorption.

Downloaded for Anonymous User (n/a) at Egyptian Knowledge Bank from ClinicalKey.com by Elsevier on March 10, 2024. For personal use only. No other uses without permission. Copyright ©2024. Elsevier Inc. All rights reserved.

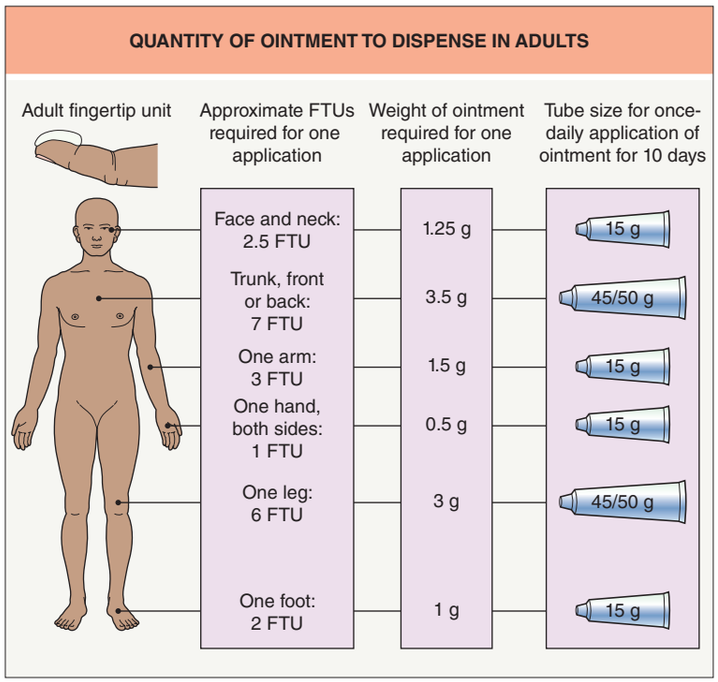

Fig. 129.1 Quantity of ointment to dispense in adults. FTU, fingertip unit. *Redrawn from Long CC, Finlay AY. The finger-tip unit – a new practical measure. Clin Exp Dermatol 1991;16:444–7.*

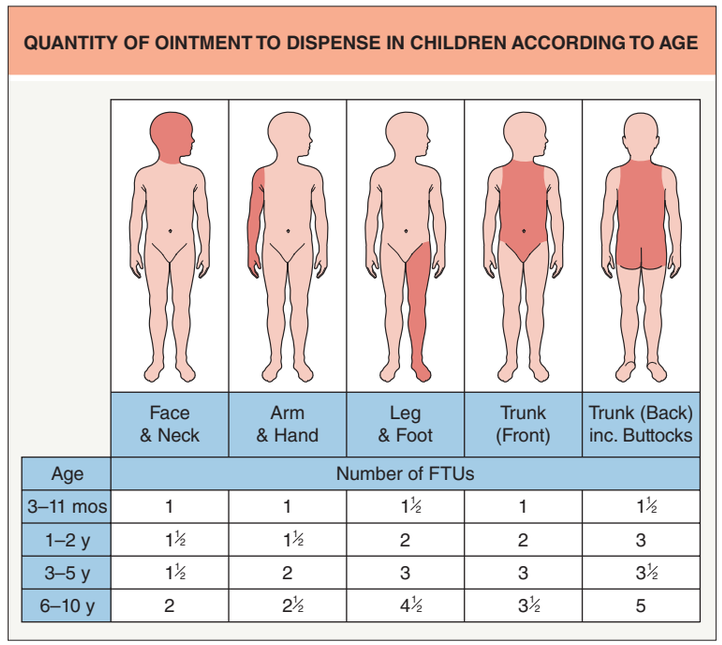

Age	Face & Neck	Arm & Hand	Leg & Foot	Trunk (Front)	Trunk (Back) inc. Buttocks
	Number of FTUs				
3–11 mos	1	1	1½	1	1½
1–2 y	1½	1½	2	2	3
3–5 y	1½	2	3	3	3½
6–10 y	2	2½	4½	3½	5

Fig. 129.2 Quantity of ointment to dispense in children, according to age. FTU, fingertip unit (in an adult). *Redrawn from Long CC, Mills CM, Finlay AY. A practical guide to topical therapy in children. Br J Dermatol 1998;138:293–6.*

A practical guide to quantifying the amount of ointment necessary to treat different areas of the body is the "fingertip unit" (FTU), which represents the amount of ointment dispensed from a 5 mm-diameter nozzle that extends from the distal crease to the tip of the index finger in an adult[1]. One FTU is equal to ~0.5 g, and the quantities required to treat various areas of the body in adults and children are presented in Figs. 129.1 and 129.2. The appropriate amount to treat the entire body of an adult man is ~20 g, therefore requiring ~250 g per week if applied twice daily. Because ~0.5 FTU (0.25 g) can treat an area equivalent to one side of an extended ("flat") hand, estimating the number of "flat hand areas" of affected skin assists in determining the amount of medication needed. For example, four "flat hand areas" would require 1 g per application and ~15 g per week if applied twice daily.

Formulations and Vehicles

A classification of topical formulations and clinical guidelines for vehicle selection are presented in Fig. 129.3. A discussion of how vehicles affect drug delivery is found in Chapter 124.

Topical Therapy During Pregnancy and Lactation

The decision to use topical medications during pregnancy and lactation should be based on the potential risk of the medication and the extent to which the condition affects the health of the woman. Use of the following topical medications during pregnancy (not a comprehensive list) is generally contraindicated: podophyllin, anthralin, lindane, chemotherapeutics (e.g. carmustine, mechlorethamine hydrochloride [nitrogen mustard], 5-fluorouracil), tazarotene, and peels with phenol or salicylic acid. In 2015, the US Food and Drug Administration (FDA) replaced pregnancy risk categories with narrative sections addressing pregnancy and lactation, which include risk summaries as well as information on pregnancy exposure registries, clinical considerations, and available data. Table 129.3 lists topical medications with minimal risk during pregnancy and lactation.

Topical Therapy in Neonates

Although the stratum corneum provides competent skin barrier function in full-term newborns under basal conditions (see Ch. 2), it undergoes structural and functional maturation during the first few weeks to months of life. Several factors result in an increased risk of systemic toxicity from topically applied medications during the neonatal period (the first 30 days of life) (Table 129.4). Systemic toxicity has been reported in neonates exposed to topical corticosteroids, salicylic acid, lindane, hexachlorophene, chlorhexidine, and propylene glycol (Table 129.5).

Combination and Rotational Topical Therapy

The advantages of using a single topical agent include improved compliance and sometimes lower cost. However, combination or rotational therapy may be employed to provide additive/synergistic effects via different mechanisms of action or to decrease potential side effects by reducing exposure to one or both agents, especially if they have different adverse-effect profiles. Examples of this strategy for topical therapy include various combinations of benzoyl peroxide, retinoids, and antibiotics to treat acne; use of a corticosteroid together with a vitamin D analogue or tazarotene to treat psoriasis; and rotating use of a corticosteroid and calcineurin inhibitor to treat atopic dermatitis.

ANTIPRURITIC AGENTS

Pruritus involves multiple components of the nervous system, including skin surface receptors, peripheral (especially unmyelinated C fibers) and central nerves, and specific brain regions (see Ch. 5). Treatment of the associated dermatologic condition, e.g. by applying topical corticosteroids to inflamed skin and moisturization of dry skin, or the underlying systemic cause remains the most effective method of alleviating itch. Topical antipruritic agents may help reduce the urge to scratch, potentially improving the efficacy of skin disease-specific therapies. Mechanisms of action of topical antipruritics include substituting a different sensation for itching, anesthetizing cutaneous nerve endings, and blocking molecular mediators of pruritus[2]. Unfortunately, a relative lack of comparative studies has made antipruritics difficult to evaluate. Commonly used agents are outlined in Table 129.6 (also see Table 5.5).

KERATOLYTICS AND HUMECTANTS

Keratolytic agents reduce the thickness of the stratum corneum via elimination of squames. This can be beneficial in diseases characterized by reduced desquamation or accelerated epidermal proliferation.

Downloaded for Anonymous User (n/a) at Egyptian Knowledge Bank from ClinicalKey.com by Elsevier on March 10, 2024. For personal use only. No other uses without permission. Copyright ©2024. Elsevier Inc. All rights reserved.

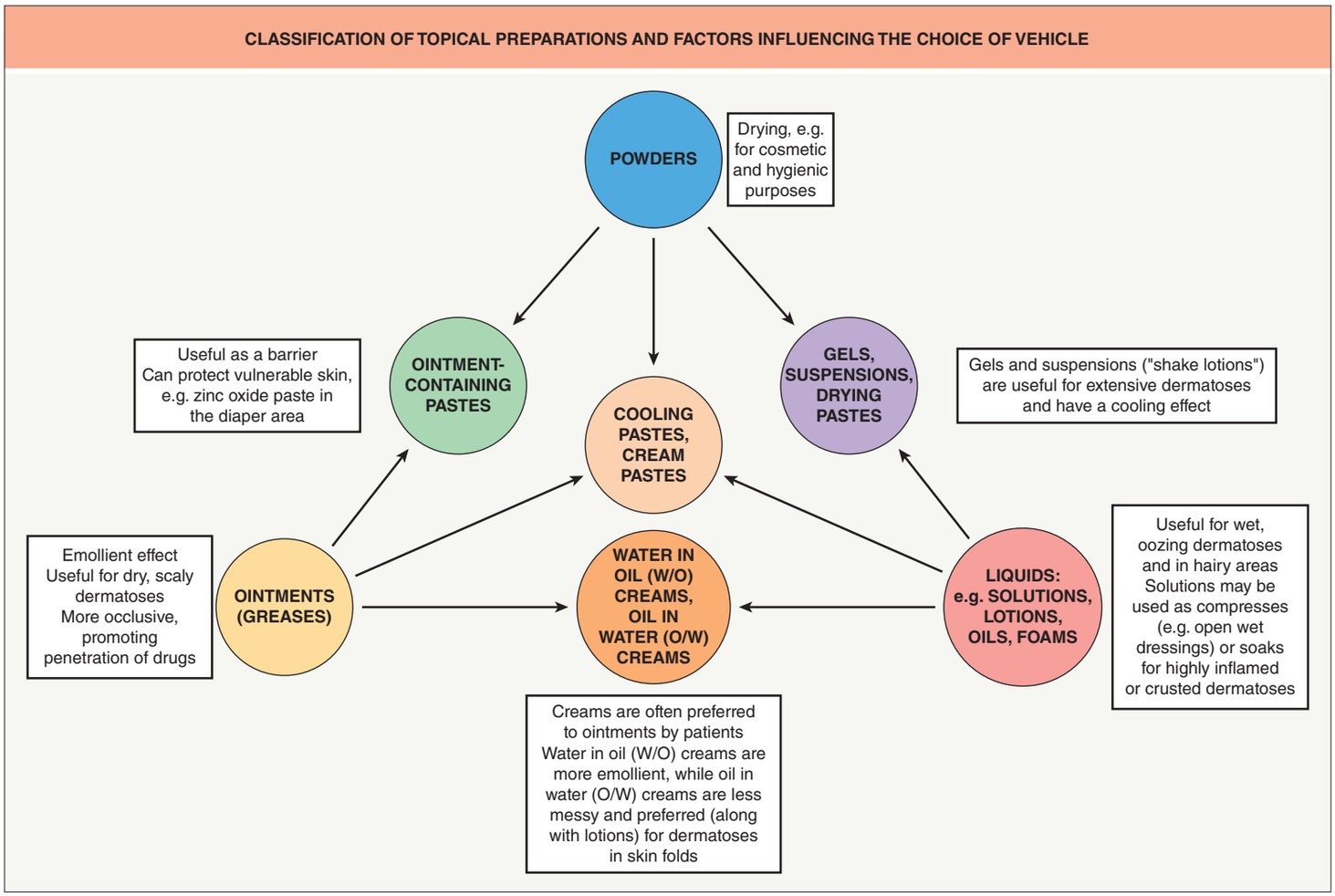

Fig. 129.3 Classification of topical preparations and factors influencing the choice of vehicle. Monophasic preparations are in primary colors. Diphasic preparations, which represent a combination of two monophasic preparations, are in secondary colors. Cooling pastes and cream pastes are triphasic preparations. Ointments, creams, gels, and pastes (highly concentrated suspensions) are semi-solids. Creams and lotions may be emulsions, i.e. contain mixtures of ≥2 liquids that are normally immiscible, brought together by emulsifiers. Foams and aerosol sprays represent liquids with pressurized gaseous propellants, and paints are alcohol-based solutions. Preparations containing alcohol or salicylic acid can lead to stinging and burning when applied to fissured or eroded skin. Vehicles may also contain preservatives, absorption promoters, and fragrances. *Adapted from Polano MK. Principles of formulation. Topical Skin Therapeutics. New York: Churchill Livingstone; 1984.*

Keratolytics and humectants are reviewed in Table 129.7, and their use in cosmeceutical products and chemical peels is discussed in Chapters 153 and 154.

SKIN-LIGHTENING AGENTS

Hydroquinone

Introduction, dosages, and indications

Hydroquinone (1,4-dihydroxybenzene) is used to treat melasma and other disorders of hyperpigmentation (see Ch. 67)[3]. In the US, 2% formulations are available over the counter, while 3% solution and 4% cream or gel require a prescription. Although twice-daily application is commonly recommended, irritant contact dermatitis can limit frequency of application. Some products contain hydroquinone combined with a sunscreen or with tretinoin (0.05%–0.1%) and a class 5–7 corticosteroid[4].

Mechanism of action

Hydroquinone reduces skin pigmentation by competing with tyrosine as a substrate for tyrosinase (the initial enzyme in melanin biosynthesis; see Ch. 65) and via selective damage to melanosomes and melanocytes via production of reactive oxygen radicals[3].

Side effects

Irritant or (less often) allergic contact dermatitis can develop. Exogenous ochronosis occasionally occurs with prolonged use of higher concentrations of hydroquinone. A variety of neoplasms have been noted to develop in rodents that received large systemic doses of the medication, but the relevance to topical therapy in humans has not been determined[3]. Concern regarding potential adverse effects related to misuse of hydroquinone led to its removal from Japanese and European markets.

Use in pregnancy

Animal reproduction studies have not consistently shown adverse fetal effects, and there are no adequate studies in pregnant women. Because of the potential for substantial systemic absorption (~30%–50%), it is recommended that hydroquinone use be avoided during pregnancy.

Monobenzyl Ether of Hydroquinone

Monobenzyl ether of hydroquinone (MBEH) 20% is infrequently used to depigment remaining uninvolved skin in patients with extensive, treatment-resistant vitiligo so as to achieve a uniform appearance (see Ch. 66). It is thought to act via competitive inhibition of tyrosinase and free radical-mediated damage of melanocytes. Depigmentation is typically long-lasting, but repigmentation (especially in a perifollicular distribution) can occur following sun exposure. Both irritant and allergic contact dermatitis are possible side effects[5].

Mequinol

Mequinol (4-hydroxyanisole) is a skin-lightening agent. A solution composed of mequinol 2% and tretinoin 0.01% is FDA-approved for

Downloaded for Anonymous User (n/a) at Egyptian Knowledge Bank from ClinicalKey.com by Elsevier on March 10, 2024. For personal use only. No other uses without permission. Copyright ©2024. Elsevier Inc. All rights reserved.

TOPICAL MEDICATIONS WITH MINIMAL RISK DURING PREGNANCY AND LACTATION	
Pregnancy	**Lactation**
Azelaic acid	Acyclovir
Ciclopirox	Bacitracin
Clindamycin	Benzoyl peroxide
Clotrimazole	Butoconazole
Erythromycin	Calcipotriene
Metronidazole*	Ciclopirox
Mupirocin	Clotrimazole
Naftifine	Erythromycin
Nystatin†	Hydroquinone
Oxiconazole	Ketoconazole
Permethrin	Metronidazole
Retapamulin	Mupirocin
Terbinafine	Nystatin
	Oxiconazole
	Terbinafine

*The CDC no longer recommends avoidance of oral metronidazole during the first trimester.
†Intravaginal topical application not advised close to term because of risk of contamination if membranes have ruptured; pregnancy category A for pastilles.

Table 129.3 Topical medications with minimal risk during pregnancy and lactation. Minimal risk refers to medications where there is no evidence of fetal risk in humans based on data from human or (if no adequate human data) animal studies. The medications listed were previously designated as FDA pregnancy category B.

FACTORS THAT INCREASE THE RISK OF SYSTEMIC TOXICITY FROM TOPICAL MEDICATIONS IN NEONATES
• Increased ratio of surface area to body weight (fourfold greater than in adults)
• Suboptimal epidermal barrier function due to the neonatal stratum corneum being on average ~30% thinner and having a higher pH (neutral instead of acidic), less hydration, and smaller corneocytes (reflecting more rapid cell turnover)
• Decreased hepatic metabolism of drugs
• Decreased renal excretion of drugs
• Increased distribution of drug, including into the CNS due to a more permeable blood–brain barrier
• Decreased plasma protein binding

Table 129.4 Factors that increase the risk of systemic toxicity from topical medications in neonates.

POTENTIAL SYSTEMIC SIDE EFFECTS OF TOPICAL MEDICATIONS	
Medication	**Systemic side effect**
Androgens	Virilization in women, children*, and fetuses
Boric acid	Generalized erythema, fever, vomiting, mental status change
Calcipotriene (calcipotriol)	Hypercalcemia, hypercalciuria
Carmustine (BCNU)	Bone marrow suppression
Chlorhexidine	Nausea, signs of ethanol intoxication
Clindamycin	Diarrhea, pseudomembranous colitis (controversial)
Corticosteroids	Iatrogenic Cushing syndrome, inhibition of hypothalamic–pituitary axis
Dimethylsulfoxide	Nausea, abdominal pain
Epinephrine (adrenaline)	Tachycardia
Estrogens	Pseudoprecocious puberty, gynecomastia, hypogonadism in men
Gentamicin	Ototoxicity
Hexachlorophene	Neurotoxicity, coma, death
Iodine	Hypothyroidism
Lidocaine and other topical anesthetics	With overdose (>5 mg/kg of lidocaine absorbed): *early/lower levels* – paresthesias (e.g. perioral tingling), tinnitus, dysgeusia (e.g. metallic taste), lightheadedness, tremors; *late/higher levels* – seizures, hypotension, arrhythmias, cardiopulmonary arrest (see Ch. 143)
Lindane	CNS toxicity
Malathion	CNS toxicity, hyperglycemia
Mechlorethamine (nitrogen mustard)	Myelosuppression
Mercury	CNS and renal toxicity, acrodynia
Minoxidil	Cardiac toxicity
Neomycin	Ototoxicity, nephrotoxicity
Phenol	Cardiac arrhythmia, death
Podophyllin	Gastrointestinal (nausea, vomiting), neurologic (mental status changes, peripheral polyneuropathy) and hematologic (thrombocytopenia, leukopenia) effects
Prilocaine–lidocaine (EMLA®)	Methemoglobinemia (perioral/acral cyanosis, vascular "mottling") related to prilocaine; see lidocaine above
Propylene glycol	Hyperosmolality, with or without lactic acidosis
Salicylic acid	Tinnitus (early sign), gastrointestinal symptoms (e.g. nausea, vomiting), CNS toxicity (e.g. confusion, delirium, seizures), metabolic acidosis with respiratory compensation (i.e. tachypnea), hypoglycemia, coma, death
Silver (silver nitrate, silver sulfadiazine)	Leukopenia, argyria

*May occur from passive transfer of paternal topical testosterone.

Table 129.5 Potential systemic side effects of topical medications. For most, the risk of these side effects is either theoretical or exists only in instances where the medication is applied to neonates or in quantities greatly exceeding normal exposure. CNS, central nervous system.

treatment of solar lentigines (formerly pregnancy category X). However, the latter product is no longer commercially available in the US. Mequinol is a substrate of tyrosinase and may serve as a competitive inhibitor of melanin biosynthesis[3].

AGENTS THAT AFFECT HAIR GROWTH

Both unwanted excessive hair and hair loss are common dermatologic complaints. Minoxidil, bimatoprost, and eflornithine are reviewed here, and topical immunotherapy with diphencyprone (DPCP) or squaric acid dibutyl ester (SADBE) for alopecia areata is covered in Chapter 69. The use of anthralin for alopecia areata is discussed below.

Minoxidil

Introduction, dosages, and indications

Originally developed as an antihypertensive agent, minoxidil has been known for decades to promote hair growth. Available in 2% and 5% solutions and a 5% foam, topical minoxidil is FDA-approved for the treatment of androgenetic alopecia in both men and women (see Ch. 69). It is also used for other forms of hair loss, including alopecia areata. Minoxidil is typically applied once or twice daily to the scalp[6].

Mechanism of action

Minoxidil causes premature termination of the telogen phase, lengthens the anagen phase, and can increase follicle size, particularly

Downloaded for Anonymous User (n/a) at Egyptian Knowledge Bank from ClinicalKey.com by Elsevier on March 10, 2024. For personal use only. No other uses without permission. Copyright ©2024. Elsevier Inc. All rights reserved.

TOPICAL AGENTS USED TO ALLEVIATE PRURITUS			
Agent	**Classification/derivation**	**Mechanism of action**	**Uses and side effects**
Pramoxine 1% (gel, lotion); in combination with 0.5%–2.5% hydrocortisone in lotion, cream, ointment, or foam	Ester anesthetic	Blocks transmission of sensory nerve impulses; hypoalgesic effect on cold pain, but not heat pain[90]; duration of effect is 2–4 hours	• Beneficial for uremic pruritus[91] and histamine-induced itch; uses include pruritus ani, notalgia paresthetica, and nonspecific mild pruritus • Allergic contact dermatitis is extremely uncommon
Menthol (up to 16% in a variety of lotions, creams, ointments, and gels)	Cyclic terpene alcohol derived from plants in the *Mentha* genus	Activates TRPM8 cation channels, which also respond to cold thermal stimuli[92,93]; possible central itch modulation via Aδ fiber and/or κ-opioid receptor activation[94]	• Provides a cooling sensation • Inconsistent antipruritic results in controlled studies • Irritation, especially of inflamed or eroded skin; rare allergic contact dermatitis
Phenol	Originally a distillation product of coal tar	Thought to act directly on cold receptors	• Cooling and antipruritic effects; found in throat sprays and lozenges • Should not be used in pregnant women or infants <6 months of age • Irritation, especially of inflamed or eroded skin
Camphor (0.25%–0.5%; various preparations)	Ketone originally derived from the camphor laurel tree (*Cinnamomum camphora*)	Local anesthetic effect	• Cooling sensation may relieve mild pruritus • Irritation, especially of inflamed or eroded skin
Capsaicin (0.025%–0.1% cream, lotion, gel, or stick; 0.025%, 8% patch)	Natural alkaloid; derived from Solanaceae family members, including hot chili peppers of the *Capsicum* genus	Activates the TRPV1 vanilloid receptor, which also responds to temperatures >43°C (109°F); repeated release of substance P from C neurons eventually leads to depletion of this neuropeptide (and reduced transmission of heat, pain, and itch)[95]	• Applied three to five times daily or via a single 1-hour application of the 8% patch • Initially evokes a sensation of warmth/burning[96], with onset of the therapeutic effect ~1 week after initiation • Transdermal patch is FDA-approved for treatment of postherpetic neuralgia • Uses include notalgia paresthetica, brachioradial pruritus, renal pruritus, prurigo nodularis, psoriatic pruritus, and itch associated with a burning sensation • Burning, stinging, and/or erythema at the application site occur in >50% of patients[97] • Hand washing after application helps to prevent contact with (and irritation of) non-affected skin, eyes, and other mucosal surfaces • Animal reproduction studies have not shown adverse fetal effects; no adequate studies in pregnant women
Doxepin 5% cream	Tricyclic compound	Potent histamine antagonist (H1 and H2); sedation via anticholinergic properties	• Applied four times daily for up to 7 days • Shown to relieve pruritus in patients with atopic dermatitis, lichen simplex chronicus, and nummular eczema[98,99] • Drowsiness due to systemic absorption occurs in ~25% of patients[100] • Occasionally irritant or (less often) allergic contact dermatitis; systemic contact dermatitis with subsequent administration of oral doxepin has been described • Contraindicated in patients with untreated narrow angle glaucoma or urinary retention and those receiving MAO inhibitors • Animal reproduction studies have not shown adverse fetal effects, and no adequate studies in pregnant women; use during lactation is not recommended
Diphenhydramine (2% cream, lotion, gel, or spray)	Antihistamine	H1 histamine antagonist; localized anesthetic effect via blockage of sodium channels	• Use is *not recommended* due to lack of efficacy as an antipruritic agent and potency as a topical sensitizer, which can lead to allergic contact dermatitis

Table 129.6 Topical agents used to alleviate pruritus. Calamine lotion is listed in Table 129.11. MAO, monoamine oxidase; TRPM8, transient receptor potential melastatin 8; TRPV1, transient receptor potential vanilloid 1.

of miniaturized follicles[6,7]. Stimulation of vascular endothelial growth factor and prostaglandin synthesis may also play a role[7]. Although oral minoxidil relaxes vascular smooth muscle by opening ATP-dependent potassium channels, this mechanism has not been definitively linked to stimulation of hair growth[7].

Side effects

While generally well-tolerated, topical minoxidil can cause dryness, irritation, and (uncommonly) allergic contact dermatitis; components of the solution formulation, in particular propylene glycol, may be responsible for these side effects. Topical minoxidil can also lead to unwanted hair growth at adjacent sites inadvertently exposed to medication (e.g. the face or ears). Systemic side effects such as headache and peripheral edema are occasionally observed.

Use in pregnancy

Animal reproduction studies with *oral* minoxidil have shown adverse effects with regard to ability to conceive and survival of offspring, but there are no adequate studies in pregnant women.

Bimatoprost

Introduction, dosages, and indications

Bimatoprost is a synthetic prostaglandin $F_{2\alpha}$ analogue that was initially utilized for the treatment of glaucoma. Following observations of thickening and elongation of the eyelashes in glaucoma patients treated with bimatoprost 0.03% ophthalmic solution (Fig. 129.4), this agent was explored as a treatment for eyelash hypotrichosis and, in 2008, FDA-approved for this indication. When bimatoprost is applied nightly to the skin of the

Downloaded for Anonymous User (n/a) at Egyptian Knowledge Bank from ClinicalKey.com by Elsevier on March 10, 2024. For personal use only. No other uses without permission. Copyright ©2024. Elsevier Inc. All rights reserved.

TOPICAL KERATOLYTICS AND HUMECTANTS				
Agent	**Dosage**	**Mechanism of action**	**Indications**	**Side effects**
Keratolytics				
Salicylic acid (2-hydroxybenzoic acid)	0.5%–40% lotion, ointment, gel, foam, solution, shampoo, cleanser, pad, plaster; OTC or prescription	Alters corneocyte adhesion, likely via disruption of desmosomal proteins; possible mild anti-inflammatory effects	0.5%–2%: comedolytic for acne 2%–10%: hyperkeratotic dermatoses 10%–40%: corns, calluses, verrucae, focal hyperkeratosis; increases penetration of other topical agents 20%–30%: chemical peels	Irritation, burning, peeling, erosions (depending on the site and concentration); allergic contact dermatitis (uncommon); systemic absorption from extensive application, especially in neonates/infants, can lead to salicylism (see Table 129.5)
α-hydroxy acids: glycolic, lactic > mandelic, tartaric, malic, and citric acids	Various concentrations and pH levels; cleanser, shampoo, lotion, cream, gel, solution, mask	Diminish strength of intercellular bonding, thereby weakening corneocyte cohesion and leading to exfoliation; act at lower, newly forming levels of the stratum corneum; higher concentrations may have dermal effects (e.g. thickening)	Xerosis, ichthyoses, other hyperkeratotic dermatoses, acne, rosacea, photoaging; chemical peels	Irritation and burning, especially when applied to inflamed or eroded/fissured skin
Humectants				
Propylene glycol	10%–70%* solution or gel	Humectant, occlusive, and keratolytic agent*	Ichthyoses, keratodermas, other hyperkeratotic dermatoses	Irritation, burning
Urea	10%–50% cream, lotion, solution, gel, or foam; OTC or prescription (higher concentrations)	Due to its hygroscopic properties; absorption of water into the stratum corneum results in increased hydration, desquamation of corneocytes, enhanced barrier function, and decreased sensitizing effects of topical irritants	Xerosis, hyperkeratotic dermatoses (e.g. keratoderma climactericum, ichthyosis, psoriasis), nail avulsion; increases penetration of other topical medications	Irritation and burning, especially when applied to inflamed or eroded/fissured skin

*Often employed at lower concentrations as a preservative and penetration enhancer in vehicles.

Table 129.7 Topical keratolytics and humectants[101–108]. Considering the low systemic absorption with topical application, use of these agents to a limited area is considered to be safe during pregnancy. Use of these agents in cosmeceutical products and chemical peels is discussed in Chapters 153 and 154, respectively.

Fig. 129.4 Unilateral trichomegaly. Bimatoprost ophthalmic solution (0.03%) was applied to one eye to treat glaucoma. *Courtesy Jean L. Bolognia, MD.*

upper eyelid margin, increased eyelash length, fullness, and darkness are noted within 16 weeks in ~75% of patients[8–11]; upon discontinuation of treatment, return toward baseline typically begins within 4 weeks.

Bimatoprost was also found to improve eyebrow hypotrichosis in a randomized, vehicle controlled trial[12]. Its potential utility for various forms of scalp alopecia (e.g. androgenetic) has also been investigated.

Mechanism of action

In animal studies, bimatoprost and other prostaglandin $F_{2\alpha}$ analogues (e.g. latanoprost) prolonged the anagen phase, increased the proportion of anagen follicles, and enlarged the dermal papilla and hair bulb during early anagen[13].

Side effects

Bimatoprost ophthalmic solution can cause pruritus and irritation of the eye, conjunctival hyperemia, and hyperpigmentation of the eyelid skin and iris, with the latter likely to be permanent[8,12]. Decreased intraocular pressure may occur but is generally not of clinical significance.

Use in pregnancy

Animal reproduction studies with high *oral* doses of bimatoprost have shown risk of spontaneous abortion and other adverse outcomes (e.g. early delivery), but systemic absorption is limited with topical use; there are no adequate studies in pregnant women.

Eflornithine

Eflornithine 13.9% cream is FDA-approved for the treatment of excessive and unwanted facial hair in women; it was discontinued by the original manufacturer in 2023. It irreversibly inhibits ornithine decarboxylase in the skin, leading to decreased polyamine synthesis and arrest of follicular matrix cell proliferation[14]. Twice-daily application for 24 weeks has been shown to significantly decrease facial hair[14], and use of eflornithine together with laser hair removal may result in more rapid and complete reduction in facial hair than laser treatment alone[15]. Eflornithine is usually well tolerated, with occasional burning or acneiform eruptions at sites of application[14]. Adverse fetal effects have been observed in animal reproduction studies when there was ingestion of eflornithine from topical application sites.

IMMUNOMODULATORY AGENTS

Imiquimod

Introduction, dosages, and indications

Imiquimod stimulates innate and adaptive immune response pathways, resulting in antiviral, antitumor, and immunoregulatory properties. Commercially available as 2.5%, 3.75%, and 5% creams, it

Downloaded for Anonymous User (n/a) at Egyptian Knowledge Bank from ClinicalKey.com by Elsevier on March 10, 2024. For personal use only. No other uses without permission. Copyright ©2024. Elsevier Inc. All rights reserved.

is FDA-approved for the treatment of: (1) anogenital warts[16]; (2) actinic keratoses (AKs) on the face or scalp[17,18]; and (3) superficial basal cell carcinoma (BCC) measuring up to 2 cm in diameter on the trunk, neck, or extremities (excluding the hands and feet)[19]. Off-label cutaneous uses with variable efficacy include treatment of common warts[20], Bowen disease (squamous cell carcinoma *in situ*)[21], nodular BCC, lentigo maligna, melanoma metastases, T cell lymphoma, Paget disease, and leishmaniasis as well as prevention of keloid recurrence following surgical excision[22–24]. Although imiquimod has been utilized to treat molluscum contagiosum, unpublished randomized controlled trials (RCTs) showed no difference in its efficacy compared to that of placebo[25].

FDA-approved regimens for imiquimod application are as follows: (1) *for anogenital warts* – 5% cream three times weekly for up to 16 weeks, or 3.75% cream daily for up to 8 weeks (~50% and ~30% clearance, respectively); (2) *for AKs* – 5% cream twice weekly for 16 weeks, or 2.5%–3.75% cream daily for two 2-week cycles separated by 2 weeks without treatment (~50% and ~35% clearance, respectively); and (3) *for superficial BCC* – 5% cream five times weekly for 6 weeks (~75% clearance). The frequency of application and duration of therapy for off-label uses vary.

Mechanism of action

The mechanism of action is depicted in Fig. 129.5[26]. In animal models, imiquimod's antiviral and antitumor activity is explained at least in part by the effects of IFN-α[27].

Side effects

The most common adverse reactions to imiquimod cream are erythema, edema, scaling, erosion, and ulceration at the site of application (Figs. 129.6 & 129.7). These reactions tend to be more intense and frequent in patients with actinic damage. Development of erosive pustular dermatosis of the scalp has been associated with the use of imiquimod for AKs of the scalp[28], and reactions with histologic findings mimicking those of lupus erythematosus have been described. Flu-like symptoms such as fatigue, fever, headache, diarrhea, and myalgias occur in ~1%–2% of patients, but systemic immune alterations have not been described.

Use in pregnancy

Animal reproduction studies with *systemic* imiquimod administration have shown adverse fetal effects, but percutaneous absorption of imiquimod cream is minimal. There are no adequate studies in pregnant women.

Topical Calcineurin Inhibitors (TCIs)

Introduction, dosages, and indications

Tacrolimus ointment and pimecrolimus cream are anti-inflammatory agents that allow treatment of eczematous and other inflammatory dermatoses without the side effects of topical corticosteroids. Tacrolimus 0.1% and 0.03% ointments are indicated for treatment of "moderate to severe" atopic dermatitis in patients ≥16 and ≥2 years of age, respectively, while pimecrolimus 1% cream is indicated for treatment of "mild to moderate" atopic dermatitis in individuals ≥2 years of age. Pimecrolimus has also been studied extensively in infants 3–23 months of age, and the American Academy of Dermatology's current guidelines recommend off-label use of pimecrolimus 1% cream and tacrolimus 0.03% ointment for children <2 years of age with mild to severe atopic dermatitis[29].

TCIs are also frequently used to treat other inflammatory skin conditions, especially when there is facial (including the eyelids) and intertriginous involvement. Examples include eczematous and seborrheic dermatitis as well as psoriasis, lichen planus (oral and genital), vitiligo, pyoderma gangrenosum, perioral dermatitis, granulomatous rosacea, cutaneous Crohn disease, lichen sclerosus, and cutaneous lesions of dermatomyositis, lupus erythematosus, and chronic graft-versus-host disease (GVHD)[30].

Mechanism of action

The mechanism of action is depicted in Fig. 129.8.

Contraindications

The TCI labels were revised in 2006 to include a boxed warning regarding a theoretical concern for risk of malignancy. However, there has been no short-term or long-term (>20 years) evidence of

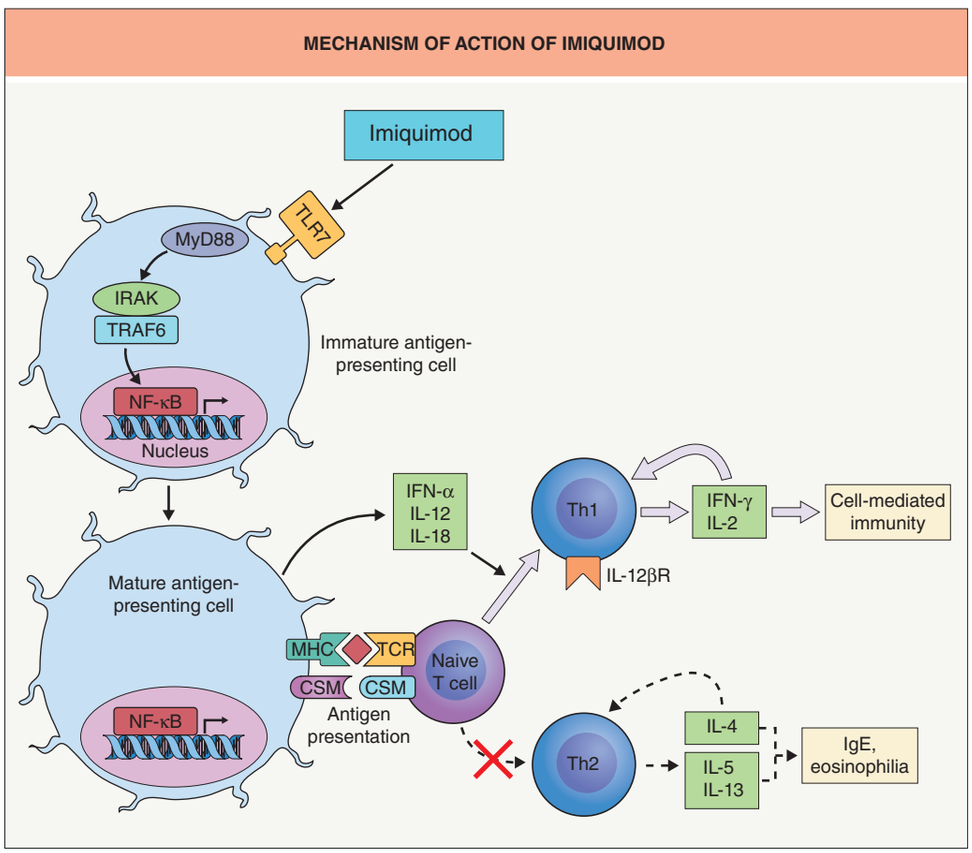

Fig. 129.5 Mechanism of action of imiquimod. Binding of imiquimod to Toll-like receptor 7 (TLR7) on antigen-presenting cells (e.g. Langerhans cells, other dendritic cells, macrophages) leads to interaction of the cytoplasmic portion of the receptor with MyD88. This facilitates association of MyD88 with interleukin (IL)-1 receptor-associated kinase (IRAK), which in turn activates TNF receptor-activated 6 (TRAF6) and ultimately results in stimulation of nuclear factor-κB-mediated signaling. Imiquimod thereby promotes antigen-presenting cell maturation and secretion of interferon (IFN)-α, IL-12, IL-18, and other cytokines, which induce IFN-γ production by naive T cells and result in enhancement of cell-mediated immunity via a Th1-type response. CSM, costimulatory molecule; MHC, major histocompatibility complex; TCR, T cell receptor.

Downloaded for Anonymous User (n/a) at Egyptian Knowledge Bank from ClinicalKey.com by Elsevier on March 10, 2024. For personal use only. No other uses without permission. Copyright ©2024. Elsevier Inc. All rights reserved.

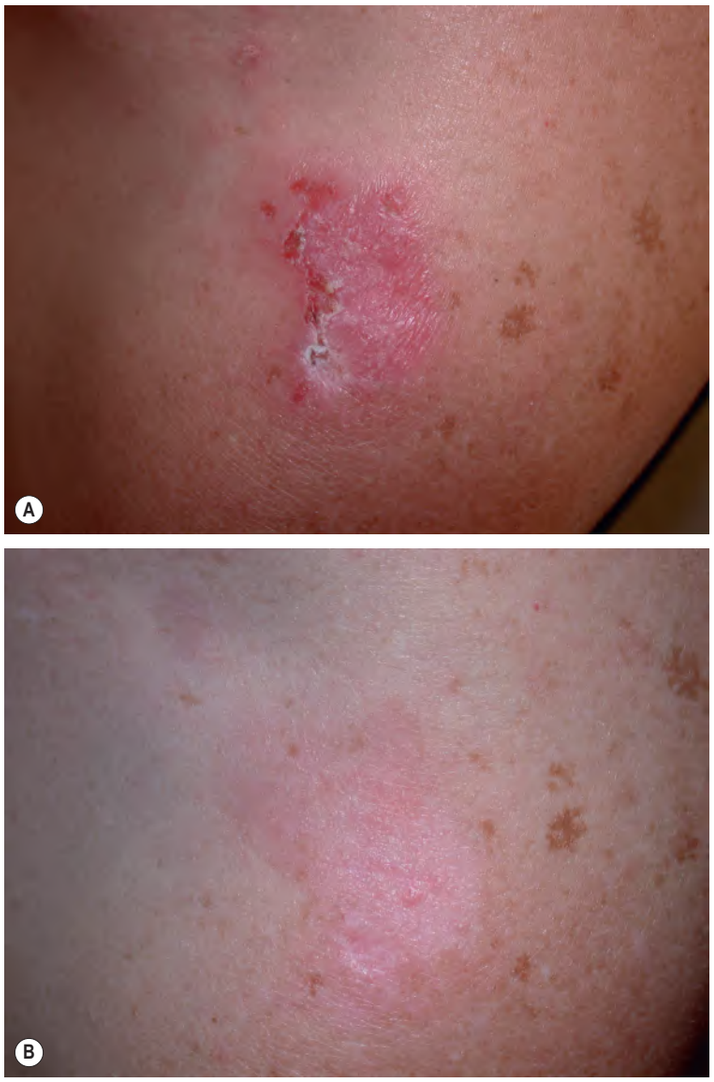

Fig. 129.6 Reaction to topical imiquimod treatment of an actinic keratosis. **A** Inflammation and erosions developed after application of imiquimod to an actinic keratosis and actinically damaged skin. **B** Following discontinuation of imiquimod, the inflammation subsided and the actinic keratosis had cleared. Note the residual hypopigmentation. *Courtesy J. Mark Jackson, MD and Jeffrey P. Callen, MD.*

Fig. 129.7 Inflammation at the site of application of imiquimod to an amelanotic lentigo maligna. The patient had residual disease despite multiple surgical procedures including skin graft placement. The inflammation did not occur until the tenth month of application. Three years later, the lesion recurred, but only within the graft. *Courtesy Jean L. Bolognia, MD.*

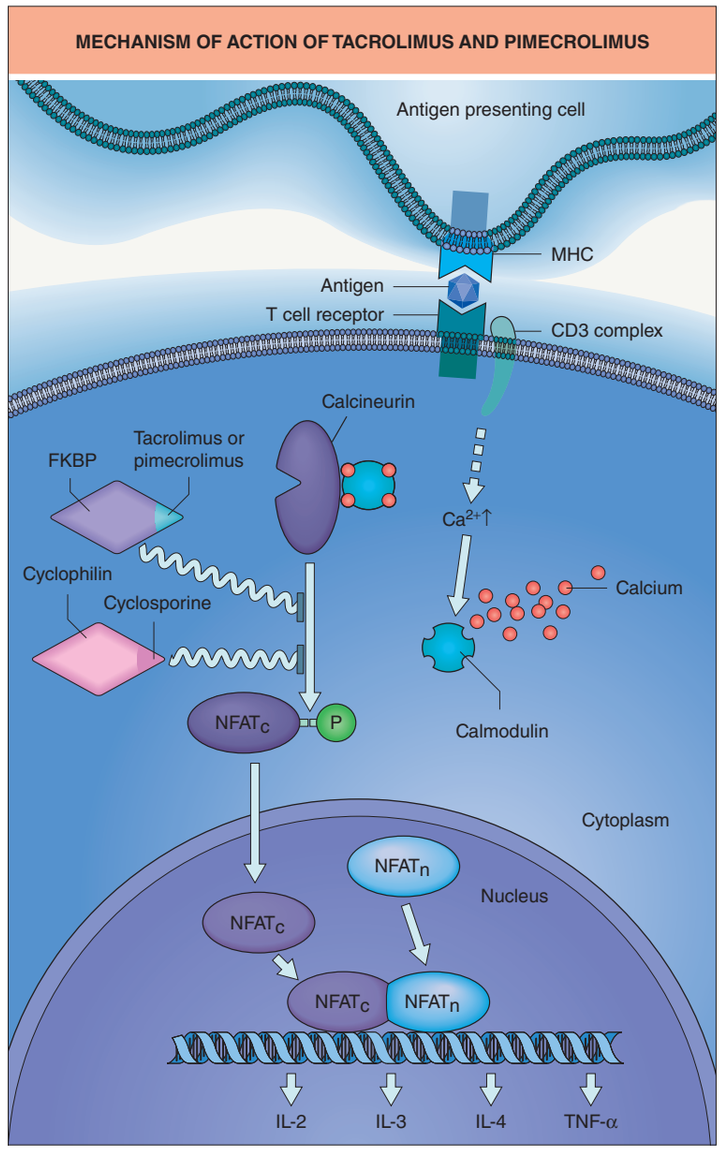

Fig. 129.8 Mechanism of action of tacrolimus and pimecrolimus. Both tacrolimus and pimecrolimus bind to the FK506-binding protein (FKBP), forming complexes that inhibit calcineurin[89]. Calcineurin normally dephosphorylates the cytoplasmic subunit of nuclear factor of activated T cells (NFAT), which then translocates to the nucleus and forms a complex that promotes transcription of proinflammatory cytokines, including the T cell mitogen IL-2. *From Nghiem P, Pearson G, Langley RG. Tacrolimus and pimecrolimus: from clever prokaryotes to inhibiting calcineurin and treating atopic dermatitis. J Am Acad Dermatol 2002:46:228–41.*

systemic immunosuppression or an increased risk for malignancy in clinical studies, systematic reviews, or post-marketing surveillance of either medication[31–34]. A task force of international experts concluded that the boxed warning is not justified and recommended its removal[33].

Because TCIs shorten the time to skin tumor formation in animal photocarcinogenicity studies, the package inserts recommend that patients minimize or avoid natural or artificial sunlight exposure. TCIs generally have negligible systemic absorption even with use on extensive areas of dermatitis, although low systemic levels have been observed following application to ulcers or eroded mucosal surfaces[35,36]. A rare exception is patients with Netherton syndrome, who have significant absorption of topical tacrolimus (but less so for pimecrolimus) that necessitates monitoring of blood levels or avoidance of TCI therapy[32,37].

Major side effects

Burning, stinging, or a sensation of warmth at sites of application are the most common side effects of TCIs. A local flushing reaction in association with alcohol consumption can also occur. There are scattered reports of allergic contact dermatitis and a rosacea-like granulomatous reaction on the face due to topical tacrolimus. *Staphylococcus aureus* colonization of the skin is actually reduced in atopic dermatitis patients treated with TCIs.

Downloaded for Anonymous User (n/a) at Egyptian Knowledge Bank from ClinicalKey.com by Elsevier on March 10, 2024. For personal use only. No other uses without permission. Copyright ©2024. Elsevier Inc. All rights reserved.

Use in pregnancy

Animal studies with *systemically* administered tacrolimus indicate harmful fetal effects only at doses that are toxic to the mother. There are no adequate studies in pregnant women.

Topical Janus Kinase (JAK) Inhibitors

Introduction, dosages, and indications

Janus kinase (JAK) inhibitors function by impeding proinflammatory cytokine-mediated signaling via the JAK-signal transducer and activator of transcription (STAT) pathway (see Ch. 128)[38]. Ruxolitinib 1.5% cream, a JAK1/2-selective inhibitor, is FDA-approved for the treatment of mild to moderate atopic dermatitis (short-term or non-continuous chronic use) and vitiligo in patients ≥12 years of age. Clear/almost clear skin and a ≥2-grade improvement were achieved by ~50% of individuals with mild to moderate atopic dermatitis treated with ruxolitinib 1.5% cream twice daily for 8 weeks[39], and >75% improvement of facial vitiligo was seen in ~30% of patients treated twice daily for 24 weeks[40].

Delgocitinib 0.25% or 0.5% ointment represents a pan-JAK inhibitor that is approved in Japan for the treatment of atopic dermatitis in adult and pediatric patients[41]. Tofacitinib 2% cream, a JAK1/3 inhibitor, has also demonstrated efficacy for atopic dermatitis in a randomized controlled study[42]. Additional dermatologic conditions for which topical JAK inhibitors have shown benefit include hand eczema, psoriasis, cutaneous lupus erythematosus, and alopecia areata[43–46].

Mechanism of action

The mechanism of action of JAK inhibitors is depicted in Fig. 128.11.

Major side effects

The most common side effects of topical JAK inhibitors include pruritus, erythema, and acne at application sites. However, the JAK inhibitor class-wide black box warning notes potential increased risks of serious infection, death, cancer, cardiovascular events, and thrombosis (see Ch. 128).

Use in pregnancy

Animal reproduction studies with high *oral* doses of tofacitinib and ruxolitinib have shown harmful fetal effects. There are no adequate studies in pregnant women.

Topical Phosphodiesterase-4 Inhibitors

Phosphodiesterase-4 (PDE-4) inhibitors function by inhibiting the degradation of cyclic AMP, which leads to decreased production of proinflammatory cytokines such as tumor necrosis factor (TNF), interferon-γ, and interleukins (ILs)-2, -4, -12, -23, and -31 (see Fig. 130.4). Crisaborole 2% ointment is a PDE-4 inhibitor that is FDA-approved for the treatment of mild to moderate AD in patients ≥3 months of age, with ~30% of these patients achieving clear/almost clear skin with a ≥2-grade improvement after 4 weeks of twice daily treatment[47]. Another PDE-4 inhibitor, roflumilast 0.3% cream, was recently FDA-approved for the treatment of plaque psoriasis (including in intertriginous sites) in patients ≥12 years of age; ~40% of such individuals achieved clear/almost clear skin with a ≥2-grade improvement after 8 weeks of once daily treatment[48]. The most common side effect of these medications is stinging or burning in the area of application. In animal reproduction studies, *oral* administration of crisaborole has not shown adverse fetal effects, but high *oral* doses of rofluminast have resulted in fetal harm. There are no adequate studies in pregnant women.

Aryl Hydrocarbon Receptor Agonists

Tapinarof is an aryl hydrocarbon receptor agonist that decreases expression of IL-17 and increases production of skin-barrier proteins such as filaggrin and loricrin as well as antioxidant enzymes. Tapinarof 1% cream is FDA-approved for the treatment of plaque psoriasis in adults, with ~40% of these patients achieving clear or almost clear skin after 12 weeks of once daily treatment[49]. Topical tapinarof is currently under investigation as a treatment for atopic dermatitis. The most common side effects include folliculitis and contact dermatitis. Animal reproduction studies have not shown harmful fetal effects, and there are no adequate studies in pregnant women.

CHEMOTHERAPEUTIC AGENTS

5-Fluorouracil

Mechanism of action

5-Fluorouracil (5-FU) is a pyrimidine analogue that interferes with DNA synthesis by irreversibly inhibiting thymidylate synthetase, which prevents cellular proliferation and results in cell death, preferentially affecting rapidly dividing cells[50]. It is also incorporated into DNA and RNA, leading to DNA breakage and decreased protein synthesis, and it disrupts the exosome complex that degrades RNA.

Indications and dosages

Topical 5-FU is used primarily to treat AKs[51], especially when there are numerous lesions, and sites of severe actinic damage without clinically evident AK lesions. In a randomized controlled trial, a ≥75% reduction in the number of AKs in a 25–100 cm^2 area on the head 12 months after completing therapy was achieved by a higher proportion of patients treated with 5-FU 5% cream (75%) than those who received imiquimod 5% cream (54%), methyl aminolevulinate photodynamic therapy (38%), or ingenol mebutate 0.015% gel (29%)[52]. 5-FU is less effective for hypertrophic AKs, owing to decreased percutaneous absorption through the thickened stratum corneum. Additional dermatologic applications of topical 5-FU include treatment of actinic cheilitis, SCC *in situ* (Bowen disease), superficial BCC, cutaneous and genital warts, porokeratoses, nail psoriasis, and extramammary Paget disease[51]; in addition, intralesional 5-FU may be of benefit for keloids. Topical 5-FU can also improve the appearance of photoaged skin via epidermal injury and subsequent dermal remodeling, similar to that seen following laser therapy[53].

5-FU is available as a cream (0.5%, 1%, and 5%) and solution (2% and 5%). Regimens vary depending on the concentration and vehicle as well as the indication and anatomic location. For example, duration of treatment is usually longer on the extremities than on the face. 5-FU is typically applied once or twice daily for 2 to 6 weeks. Pretreatment with a topical retinoid for 2 weeks can increase efficacy on the extremities and trunk. Application of topical calcipotriene (calcipotriol) 0.005% ointment together with 5-FU 5% cream (e.g. both twice daily for 4 days) induces thymic stromal lymphopoietin (TSLP) production and optimizes $CD4^+$ T cell-mediated immunity, resulting in a synergistic effect against AKs[54]. An office-based technique utilized for severely photodamaged extremities is weekly application of 5-FU (~10–20 g/extremity) that is then occluded by a zinc oxide-impregnated wrap.

Side effects

During treatment of AKs and photodamage, the skin progresses through stages of erythema (sometimes painful and associated with edema), crusted erosions, and re-epithelialization. The principal side effects are related to this localized inflammatory response (Fig. 129.9), which is occasionally followed by residual pigmentary changes. A mid-potency topical corticosteroid can be applied for symptomatic relief once peak inflammation has been attained. Systemic adverse events are rare, and systemic levels of 5-FU after topical application are very low[51].

Contraindications and use in pregnancy

Use of 5-FU is contraindicated in patients with a history of hypersensitivity to this agent and those with dihydropyrimidine dehydrogenase deficiency. 5-FU is potentially teratogenic (formerly pregnancy category X), and its use during pregnancy and lactation is contraindicated.

Mechlorethamine Hydrochloride

Introduction, dosages, and indications

Mechlorethamine hydrochloride (HCl), a form of nitrogen mustard, was introduced in 1959 and is used to treat limited or generalized patch/plaque-stage mycosis fungoides (MF). Concentrations ranging from 10 to 40 mg/dl (0.01%–0.04% w/w) can be compounded in an ointment or (less often) aqueous solution. Mechlorethamine 0.016% w/w gel is FDA-approved for stage 1 A/1B MF. Topical mechlorethamine

Downloaded for Anonymous User (n/a) at Egyptian Knowledge Bank from ClinicalKey.com by Elsevier on March 10, 2024. For personal use only. No other uses without permission. Copyright ©2024. Elsevier Inc. All rights reserved.

Fig. 129.9 Reactions to topical 5-fluorouracil. **A** Inflammation with erythema and crusting at sites of actinic keratoses on the forehead. **B** More severe inflammatory response with diffuse erythema and crusting in a patient treated for actinic keratoses. **C** Inflammation of actinic keratoses and areas of photodamage. **D** Large red–purple patches at sites of application on the upper chest in a patient with severe photodamage. *D, Courtesy Jean L. Bolognia, MD.*

is typically applied daily to affected areas until clearance is achieved, which typically takes 10–12 months with an ointment, 1–4 months with a solution, and 6–12 months with the gel[55]. Less often the entire body is treated, excluding the genitalia and applying sparingly to the skin folds.

Older studies suggested that treatment with mechlorethamine ointment or solution could result in a complete response (CR) rate of ~35%–75% in patients with patch/plaque-stage MF[56]. However, in a more recent 12-month randomized trial, the CR rate was 14% for 0.02% gel and 12% for an Aquaphor®-based 0.02% ointment; response rates rose to 59% and 48%, respectively, when partial responses were included[57].

Mechanism of action

Mechlorethamine is an alkylating agent (i.e. donates alkyl groups to DNA), with cytotoxicity that preferentially affects rapidly dividing cells. Immunostimulatory effects have also been postulated to have a role in treatment of patients with MF[56].

Side effects

Irritant and/or allergic contact dermatitis occurs in at least half of patients and may result in interruption of treatment. However, irritant reactions may improve with continued use, and patients can be desensitized if necessary. Other potential side effects include pruritus, xerosis, bacterial skin infections, vesiculation, ulceration, hyperpigmentation, urticaria, anaphylaxis, and (with prolonged use) development of SCC[56].

Use in pregnancy

Mechlorethamine can cause adverse fetal effects, and its use during pregnancy or lactation is contraindicated.

Carmustine

Introduction, dosages, and indications

Topical nitrosoureas have been utilized in the treatment of MF since 1972[58], but their use is declining. Carmustine (1,3-bis [2-chloroethyl]-1-nitrosourea; BCNU) currently represents a second- or third-line therapeutic option for MF, due to the potential for hematologic complications secondary to systemic absorption. It is available as an aqueous solution and ointment. Carmustine is applied once or twice daily until clearance of the treated areas occurs, which typically requires 1–4 months with the aqueous solution and 6–12 months with the ointment. A complete response is achieved in 85% of patients with limited patch/plaque-type disease (T1) and ~50% of those with generalized patch/plaque-type disease (T2)[56,59].

Mechanism of action

Carmustine is a nitrosourea alkylating agent that produces alkylation and subsequent cross-linking of DNA, thereby disrupting DNA synthesis and resulting in cytotoxicity that preferentially affects dividing cells[56].

Side effects

Erythema, tenderness, bullae, and persistent telangiectasias can develop at application sites[56]. Allergic contact dermatitis occurs less frequently than with mechlorethamine. However, higher levels of systemic absorption (5%–30% of the administered dose) can lead to side effects such as mild to moderate myelosuppression[60].

Use in pregnancy

Carmustine can cause adverse fetal effects, and its use during pregnancy or lactation is contraindicated.

VITAMIN D ANALOGUES

Mechanism of action

The skin serves as both a site of vitamin D biosynthesis (see Fig. 51.11) and a target organ for its ultimate activity. The cutaneous effects of 1,25-dihydroxyvitamin D_3 (calcitriol, the active form of vitamin D) include inhibiting proliferation and promoting differentiation of keratinocytes, as well as decreasing production of inflammatory mediators such as IL-2, IL-6, IL-8, interferon-γ, and chemokines[61]. Vitamin D exerts its regulatory functions by binding to vitamin D receptors (VDRs) on keratinocytes, melanocytes, Langerhans cells, macrophages, T cells, and fibroblasts.

Downloaded for Anonymous User (n/a) at Egyptian Knowledge Bank from ClinicalKey.com by Elsevier on March 10, 2024. For personal use only. No other uses without permission. Copyright ©2024. Elsevier Inc. All rights reserved.

Topical agents and their indications

Several topical vitamin D analogues are available for clinical use: calcipotriene, calcitriol, tacalcitol, and maxacalcitol; their formulations and dosing are outlined in Table 129.8. The primary indication for these agents is the treatment of psoriasis[62–66], but they have been used to treat other skin conditions such as vitiligo, morphea, ichthyoses, and Hailey–Hailey disease. Application of a vitamin D analogue in combination with a high-potency topical corticosteroid in patients with psoriasis can have greater efficacy and more rapid onset of action than either agent alone, as well as less irritation than the vitamin D analogue alone[63]. Additive benefits can also occur when vitamin D analogues are used together with acitretin, cyclosporine, or phototherapy for psoriasis or with phototherapy for vitiligo; the vitamin D analogue should be applied after phototherapy sessions to avoid degradation by UV light.

Side effects

The most common side effects are irritation, burning, and stinging at the application site, which limits use of vitamin D analogues on the face and in intertriginous areas. Allergic contact dermatitis has been described with calcipotriene. The systemic effects of vitamin D and its analogues include releasing calcium from the bone, increasing renal tubular reabsorption and intestinal absorption of calcium, and decreasing parathyroid hormone release. Use of excessive amounts of topical vitamin D analogues can lead to hypercalcemia and hypercalciuria. Parathyroid hormone levels should be monitored if use exceeds recommended amounts (see Table 129.8). Patients with renal disease and those receiving medications that can increase the serum calcium level (e.g. thiazide diuretics, high doses of oral vitamin D) may be at increased risk of developing hypercalcemia.

Use in pregnancy

Animal reproduction studies with *systemically* administered calcipotriene and calcitriol have demonstrated fetal skeletal abnormalities. There are no adequate studies in pregnant women.

MISCELLANEOUS AGENTS

Topical Sirolimus (Rapamycin)

Introduction, dosages, and indications

Sirolimus (rapamycin) is a *m*ammalian (*m*echanistic) *t*arget of *r*apamycin (mTOR) inhibitor with antiproliferative and immunomodulatory effects. Uses of *systemic* sirolimus include rejection prophylaxis and probable reduction of cutaneous SCC risk in solid organ transplant recipients; prophylaxis and treatment of GVHD; and treatment of lymphangioleiomyomatosis and other tumors associated with tuberous sclerosis complex (TSC; see Ch. 61), Kaposi sarcoma, kaposiform hemangioendothelioma, and lymphatic malformations[67]. *Topical* sirolimus has been utilized to treat angiofibromas, other TSC-related skin lesions, superficial lymphatic malformations, port-wine birthmarks (together with pulsed dye laser therapy), psoriasis, epidermal and sebaceous nevi, acanthosis nigricans, and confluent and reticulated papillomatosis (CARP)[68–77]. Sirolimus 0.2% gel is FDA-approved for the treatment of facial angiofibromas in patients ≥6 years of age with TSC. Application of sirolimus 0.1%–1% ointment, gel, cream, or solution (e.g. Rapamune® 1 mg/ml [0.1%]) once or twice daily to the facial angiofibromas of TSC usually leads to flattening and reduced erythema within 3 months, with better results in children than adults[69–74].

TOPICAL VITAMIN D_3 AND ITS ANALOGUES		
Agent	**Available formulations**	**Maximum weekly dose**
Calcipotriene (calcipotriol) 0.005% (50 mcg/g)	Cream, ointment, solution, foam; combined with betamethasone dipropionate 0.064% in an ointment, suspension, and foam	100 g
Calcitriol [1,25$(OH)_2D_3$] 3 mcg/g	Ointment	200 g
Tacalcitol [1,24$(OH)_2D_3$] 4 mcg/g*	Ointment, lotion	70 g
Maxacalcitol 25 mcg/g*	Ointment, lotion	70 g
*Not available in the US.		

Table 129.8 Topical vitamin D_3 and its analogues. These agents are typically applied twice daily. In general, treatment of >30% of the body surface area is not recommended. Calcipotriene is the US Adopted Name (USAN) and calcipotriol is the International Nonproprietary Name (INN).

Mechanism of action

Sirolimus binds to the FK506 binding protein FKBP12, forming a complex that inhibits mTOR (see Fig. 61.12). This leads to reduced proliferation and protein synthesis of T lymphocytes and other immune cells as well as decreased vascular endothelial growth factor (VEGF) production.

Side effects

Local skin irritation is more common with a gel or solution formulation than with an ointment[69,70]. Little to no systemic absorption has been observed with topical therapy[70–74].

Use in pregnancy

Animal reproduction studies with *oral* sirolimus have demonstrated adverse fetal effects. There are no adequate studies in pregnant women.

Diclofenac Sodium

Diclofenac sodium 3% in a gel vehicle containing hyaluronic acid is FDA-approved for treatment of AKs. This NSAID inhibits cyclooxygenase (COX)-2 and (to a lesser degree) COX-1. Its mechanism of action against AKs is thought to involve induction of apoptosis, alteration of cellular proliferation, and inhibition of angiogenesis. Twice-daily application for 60–90 days results in AK clearance rates of up to 30%–50%, with potential side effects including irritant, allergic, and photoallergic contact dermatitis. Animal reproduction studies have failed to demonstrate fetal risk, and there are no adequate studies in pregnant women.

Ingenol Mebutate

Ingenol mebutate, a diterpene ester from the *Euphorbia peplus* plant, was FDA-approved as a topical treatment for AKs[78–80]. However, this medication has been withdrawn from the market in the US and Europe due to its association with an increased risk of keratinocyte carcinoma. Application of ingenol mebutate 0.015% or 0.05% gel to areas with AKs on the face/scalp or trunk/extremities, respectively, once daily for 2–3 consecutive days led to a clearance rate of ~40%. This agent induces cell death in proliferating keratinocytes via disruption of the plasma membrane and mitochondria; it also triggers an inflammatory response that eradicates residual tumor cells[78–80]. Erythema, scaling, and crusting develop in most patients[78]; less frequently, swelling, vesiculation, ulceration, and dyspigmentation occur. Animal reproduction studies have demonstrated adverse fetal effects, and there are no adequate studies in pregnant women.

Tar

Introduction and indications

Topical tar has served as a skin-directed therapy for >2000 years, since the Greek physician Dioscorides applied "asphalt" to manage several cutaneous diseases[81]. Among the various types of tar (e.g. wood, bituminous [shale], petroleum, coal), coal tar is most often used as a dermatologic treatment. Currently, tar is utilized primarily in the management of psoriasis and several forms of dermatitis (e.g. seborrheic, nummular, atopic, hand), most commonly in conjunction with other therapeutic modalities. The classic Goeckerman regimen employs topical tar in combination with UVB radiation for the treatment of psoriasis[82].

Dosages

Coal tar in concentrations of 0.5% to 10% is available and can be compounded in a broad range of vehicles, including ointment, lotion, gel, foam, solution, oil, shampoo, and soap. *Liquor carbonis detergens* is a distillate of crude coal tar that is typically used in concentrations of 3%–10%.

Downloaded for Anonymous User (n/a) at Egyptian Knowledge Bank from ClinicalKey.com by Elsevier on March 10, 2024. For personal use only. No other uses without permission. Copyright ©2024. Elsevier Inc. All rights reserved.

Mechanism of action

Coal tar is thought to suppress DNA synthesis, which may lead to normalization of epidermal differentiation in conditions such as psoriasis[81]. It appears to have anti-inflammatory, antimicrobial, and antipruritic effects. In animal studies, tar has been found to decrease sebum secretion. Coal tar (but not other forms of tar) has a photosensitizing effect in the 330–550 nm range of the UVA and visible light spectra[81].

Side effects

The unpleasant odor, messiness, and staining potential of topical tar limit its use. Acneiform eruptions, folliculitis, and irritant contact dermatitis (including pustules within plaques of psoriasis) may occur at application sites, and "tar smarts" can develop following exposure to UVA radiation. Ever since Sir Percivall Pott described an increased risk of scrotal cancer in chimney sweepers in 1775, tar has been implicated as a potential carcinogen[81]. However, the evidence that topical tar formulations used in the treatment of skin disease result in an increased risk of skin cancer is inconclusive.

Use in pregnancy

Animal reproduction studies have shown adverse fetal effects, and there are no adequate studies in pregnant women. Use in the first trimester is not recommended.

Anthralin

Introduction, dosages, and indications

Anthralin, the synthetic form of the chrysarobin found in the bark of the South American araroba tree, has been used to treat dermatologic conditions for >80 years[83]. It is available in 0.5% and 1% creams. Although no longer commonly used for psoriasis, short-contact anthralin therapy, with gradual increases in the application time ± concentration, continues to be employed to treat alopecia areata via induction of an irritant effect (Table 129.9)[83].

Mechanism of action

Anthralin induces a brisk inflammatory response at sites of application, which may result from generation of extracellular oxygen free radicals[83]. Inhibition of mitochondrial respiration and cell growth are thought to reduce keratinocyte proliferation and lead to antipsoriatic effects.

Side effects

Use of anthralin is limited by irritation at application sites (depending on the concentration and contact time) and staining of skin, clothing, and household items (e.g. bed sheets, furniture). Staining and irritation can be ameliorated by application of triethanolamine 10% cream to treatment sites after removal of the anthralin-containing product.

SAMPLE PROTOCOL FOR SHORT-CONTACT ANTHRALIN THERAPY FOR ALOPECIA AREATA
• Anthralin 0.5% cream is applied sparingly to affected areas of the scalp daily, followed by washing with shampoo/soap and water • An initial application time of 10 minutes is increased in 10-minute increments every 4–5 days until slight irritation (e.g. erythema, scaling, pruritus) occurs • If excessive irritation develops, treatment is withheld for several days and resumed at the last tolerated application time • If there is no irritation with a 60-minute contact time, 1% anthralin is applied for 10 minutes and application times increased as above • If there is no irritation with 1% anthralin applied for 60 minutes, overnight application is considered • Initial responses are typically seen within 12 weeks; cosmetically acceptable responses require a mean of 24 weeks
Additional information
• Brownish staining of treated areas of the scalp and hair is expected • To prevent staining of clothing, bedding, and furniture, patients should wash their hands thoroughly after applying anthralin and avoid touching fabrics with their scalp until it has been washed off • Avoid getting anthralin into the eyes; do not apply to eyelids or eyelashes • Special care should be taken in sensitive areas (areas of scalp near the ears, eyebrows)

Table 129.9 Sample protocol for short-contact anthralin therapy for alopecia areata. *Courtesy Julie V. Schaffer, MD and Jean L. Bolognia, MD.*

Use in pregnancy

There are no adequate studies in animals or pregnant women.

Podophyllin and Podophyllotoxin

Introduction, dosages, and indications

Podophyllin resin is a crude extract from the May apple plant (*Podophyllum peltatum* or *Podophyllum emodi*) that has been employed for decades to treat condylomata acuminata. However, the concentration of its most active ingredient is not standardized in the 10%–25% solutions that are applied in the physician's office weekly and washed off 1 to 4 hours later[84]. In contrast, podophyllotoxin is available in a stable and standardized 0.5% solution and gel as well as a 0.15% cream. These compounds lack the mutagens that are found in podophyllin and can be applied by the patient, usually twice daily for three consecutive days each week for 4–6 weeks. Reported clearance rates for condylomata acuminata range from 30%–60% with podophyllin and from 45%–75% with podophyllotoxin[84].

Mechanism of action

Podophyllin and podophyllotoxin act by arresting mitosis through reversible binding to tubulin.

Side effects

Common adverse effects associated with both podophyllin and podophyllotoxin include burning, erythema, and skin breakdown at application sites. The extent of irritation may be reduced by application of petrolatum to unaffected surrounding skin. Because of its percutaneous absorption, application of large amounts of podophyllin can result in systemic toxicity (see Table 129.5).

Use in pregnancy

Use of podophyllin during pregnancy is contraindicated due to its teratogenic effects. However, a study of pregnant women treated with podophyllotoxin did not show an increased risk of adverse fetal outcomes.

Cantharidin

Introduction, dosages, and indications

Cantharidin is a vesicant derived from "blister beetles" in the Coleoptera order and Meloidae family. It has been used since the 1950s to treat warts and molluscum contagiosum (MC). Although cantharidin met the safety requirements outlined by the Food, Drug, and Cosmetic Act of 1938, it lost its FDA approval in 1962 when its manufacturers failed to submit required efficacy data[85]. A 0.7% concentration of cantharidin is available in a film-forming solution. VP-102, a drug-delivery device containing cantharidin 0.7% plus gentian violet, was FDA approved for the in-office treatment of MC in 2023. This formulation, was shown in randomized controlled studies to result in complete MC clearance in ~50% of patients treated at 3-week intervals for 12 weeks[86]. Another formulation that is primarily used for warts combines 1% cantharidin with 2% podophyllin and 30% salicylic acid.

A thin film of cantharidin is typically applied to lesions in the office. Occlusion may be used after drying, especially for treatment of warts. The residual film is washed off thoroughly with soap and water or rubbing alcohol by the patient (or a parent) 2 to 6 hours after application, or in 24 hours for VP-102. Blisters typically form over the next 12–24 hours, followed by superficial erosions; healing of treated areas (with temporary residual erythema) occurs over a period of 4–7 days[85]. Benefits of cantharidin use include painless application (particularly advantageous in young children) and a lack of scarring.

Mechanism of action

Cantharidin acts via release of neutral serine proteases that cause desmosomal plaque degeneration, leading to detachment of desmosomes from

Downloaded for Anonymous User (n/a) at Egyptian Knowledge Bank from ClinicalKey.com by Elsevier on March 10, 2024. For personal use only. No other uses without permission. Copyright ©2024. Elsevier Inc. All rights reserved.

tonofilaments; resultant acantholysis is intraepidermal and therefore non-scarring[85].

Side effects

The blisters and erosions that form after cantharidin treatment can be painful or pruritic, and postinflammatory hypopigmentation may take several months to resolve. Use of cantharidin to treat warts occasionally results in a "doughnut wart" due to clearance in the center but not at the periphery of the lesion. Cantharidin poisoning has been described following ingestion, with sequelae including blistering and erosions in the mouth and gastrointestinal tract as well as dysuria, hematuria, and renal failure. Standard in-office application of cantharidin, however, does not generally cause systemic effects.

Sulfur

Introduction

Sulfur, a yellow non-metallic element, has been employed as a treatment for seborrheic dermatitis, rosacea, acne, tinea versicolor, and scabies. Sulfur is typically used in concentrations of 2%–10%, often in combination with a second agent, e.g. 2% sulfur plus 2% salicylic acid in shampoos (for seborrheic dermatitis) or 5% sulfur plus 10% sodium sulfacetamide in a cream, suspension, or gel (for rosacea, acne, and seborrheic dermatitis; see Ch. 127). Application of 5%–10% sulfur ointment to the entire body for 2–3 consecutive nights represents a classic scabies treatment; however, it is inferior to topical permethrin therapy.

Mechanism of action

Sulfur has antibacterial, antifungal, and keratolytic properties.

Side effects

An offensive odor similar to that of rotten eggs limits the use of sulfur in the absence of masking fragrances. Side effects are generally mild and include dryness and pruritus.

Contraindications

Topical sulfur is contraindicated in patients with a sensitivity to sulfur.

Use in pregnancy

Topical sulfur (5%–10%) has been used to treat scabies in young infants and pregnant or lactating women, but safety data are lacking.

Azelaic Acid

Introduction and indications

Azelaic acid, a naturally occurring dicarboxylic acid, is used in the treatment of rosacea, acne, melasma, and postinflammatory hyperpigmentation.

Mechanism of action

Azelaic acid inhibits the production of free radical oxygen by neutrophils. This reduces oxidative tissue injury at sites of inflammation and decreases melanin production. Studies have also demonstrated selective cytotoxic and antiproliferative effects on hyperactive and abnormally proliferating melanocytes, with little effect on normal melanocytes. It may act as a competitive inhibitor of tyrosinase, further explaining its skin-lightening effects[87,88]. In addition, azelaic acid has antimicrobial activity against *Cutibacterium* (formerly *Propionibacterium*) *acnes* and *Staphylococcus epidermidis* as well as moderate anticomedogenic properties via modification of epidermal keratinization.

Dosages

Azelaic acid, which is applied twice daily, is available by prescription in a 20% cream and 15% gel as well as in 10%–14% over-the-counter formulations.

Side effects

Azelaic acid may cause mild to moderate irritant contact dermatitis (e.g. dryness, peeling, erythema), which often subsides after 2 to 4 weeks of treatment.

Use in pregnancy

Azelaic acid is considered safe to use during pregnancy.

Topical Immunotherapy

A sample protocol for topical immunotherapy with squaric acid dibutyl ester (SADBE) for cutaneous warts is outlined in Table 129.10, and use of SADBE or diphencyprone for alopecia areata is discussed in Chapter 69.

The Old and the New

Topical agents of historical interest are presented in Table 129.11. Many newer barrier-repair creams and moisturizers have purported benefit in

SAMPLE PROTOCOL FOR TOPICAL IMMUNOTHERAPY WITH SQUARIC ACID DIBUTYL ESTER FOR CUTANEOUS WARTS
• Sensitize with a 2% SADBE solution in acetone applied to a small (e.g. 2 cm × 2 cm) area on the inner aspect of the upper arm or medial thigh; cover with a dressing and do not wash for 24 hours • After 1 week (2 weeks if the initial reaction was severe), apply 0.2% SADBE solution to non-facial warts; cover with a light dressing and wash after 12–24 hours • Apply approximately twice weekly to warts; can increase or decrease the length of time between treatments depending on the duration of the reaction, with repeat application once the erythematous/eczematous reaction has subsided • If there is no inflammation or response of the warts after 2–4 weeks, increase the concentration to 0.5% (and subsequently to 1% and 2% as needed); decrease concentration (e.g. from 0.2% to 0.1%) and/or amount applied if excessive inflammation, e.g. more than mild erythema and pruritus • Responses are usually seen within 3 months, with complete clearance in 60%–80% of patients after a mean of 6–8 weeks
Additional information
• The acetone solution should be applied using a cotton-tip applicator • SADBE should be refrigerated and protected from light • Side effects include severe or widespread eczematous reactions (which can be treated with topical or, if required, systemic corticosteroids), lymphadenopathy, and postinflammatory pigment alterations (especially in patients with darkly pigmented skin)

Table 129.10 Sample protocol for topical immunotherapy with squaric acid dibutyl ester (SADBE) for cutaneous warts. This is not an FDA-approved medication.

TRADITIONAL TOPICAL MEDICATIONS		
Agent	**Components**	**Classic uses**
1-2-3 paste	Burow's solution, petrolatum, zinc oxide	In the diaper area as a protective barrier to treat and prevent irritant dermatitis Hand eczema, erosions, ulcerations
Aqueous silver nitrate 10% solution*	Silver nitrate	Small recalcitrant ulcerations Excess granulation tissue, bleeding – silver nitrate applicators ("sticks")
Black cat*	Acetone, collodion, crude coal tar	Psoriasis, lichen simplex chronicus, nummular eczema, hypertrophic lichen planus
Burow's solution	Aluminum acetate	Weeping, macerated, and/or infectious skin conditions, especially in intertriginous and acral sites (e.g. acute allergic contact dermatitis, tinea pedis/cruris, candidiasis)

Table 129.11 Traditional topical medications.

Continued

Downloaded for Anonymous User (n/a) at Egyptian Knowledge Bank from ClinicalKey.com by Elsevier on March 10, 2024. For personal use only. No other uses without permission. Copyright ©2024. Elsevier Inc. All rights reserved.

TRADITIONAL TOPICAL MEDICATIONS		
Agent	**Components**	**Classic uses**
Calamine lotion	Zinc oxide, ferric oxide, glycerin, bentonite magma, calcium hydroxide solution (lime water)	Acute and subacute pruritic dermatoses, especially acute allergic contact dermatitis
Castellani paint (carbol fuchsin)	Phenol, resorcinol, basic fuchsin (without the latter in colorless version)	Fissures, primarily on digits in the setting of chronic hand dermatitis Cutaneous candidiasis, tinea pedis/cruris, pustular dermatoses of the hands and feet
Chrysarobin*	Chrysarobin, chloroform	Chronic paronychia
Fluffy tannic acid powder*	Fluffy tannic acid, bentonite, kaolin	Hyperhidrosis, contact dermatitis of the hands/feet
Gentian violet solution	Gentian violet	Candidiasis, tinea pedis/cruris
P&S® liquid	Mineral oil, glycerin, phenol	Psoriasis/sebopsoriasis with excessive hyperkeratosis (especially of the scalp)
Potassium permanganate	$KMnO_4$	Weeping, macerated, and/or infectious skin conditions, especially in intertriginous and acral sites (e.g. tinea cruris/pedis, candidiasis)
Schamberg lotion*	Menthol, phenol, zinc oxide, calcium hydroxide solution, olive oil	Acute and subacute pruritic dermatoses
Whitfield ointment	Benzoic acid (6%), salicylic acid (3%)	Tinea pedis
*Primarily of historical interest.		

Table 129.11 Traditional topical medications.

EXAMPLES OF NEWER PRESCRIPTION BARRIER-REPAIR/ MOISTURIZING AGENTS	
Agent	**Active ingredients**
Atopiclair®/Pruclair™ cream	Glycyrrhetinic acid (licorice root), *Vitis vinifera* (grape vine) extract, *Butyrospermum parkii* (shea butter), hyaluronic acid, telmesteine
Eletone® cream	70% oil (mineral oil, white petrolatum) dispersed in 30% water
EpiCeram® emulsion	3 : 1 : 1 molar ratio of ceramide, cholesterol and free fatty acids (e.g. capric, linoleic, palmitic acids)
Hylatopic® (Plus) emollient foam cream, and lotion	*Theobroma grandiflorum* seed butter, hyaluronic acid, ceramide (latter in "Plus" version)
MimyX®/PruMyx™ cream	Palmitamide monoethanolamine, palm glycerides, hydrogenated lecithin, squalane, olive oil
Neosalus® foam	Dimethicone, stearic acid
Promiseb™ cream	Glycyrrhetinic acid, *Vitis vinifera* extract, *Butyrospermum parkii*, piroctone olamine, hydrogenated castor oil, telmesteine
Tetrix™ cream	Aluminum magnesium hydroxide stearate, cyclomethicone, dimethicone, hexyl laurate

Table 129.12 Examples of prescription barrier-repair/moisturizing agents. These agents are FDA-approved as "medical devices" and available by prescription. Over-the-counter barrier-repair moisturizers containing ceramides or "pseudoceramides" and filaggrin breakdown products are also available.

the management of various dermatoses, such as atopic dermatitis and irritant contact dermatitis; examples of these agents and their active ingredients are listed in Table 129.12.

Additional figures and table available in our eBook (see inside front cover for access code).

REFERENCES

1. Long CC, Finlay AY. The finger-tip unit–a new practical measure. *Clin Exp Dermatol*. 1991;16:444–447.
2. Hercogova J. Topical anti-itch therapy. *Dermatol Ther*. 2005;18:341–343.
3. Draelos ZD. Skin lightening preparations and the hydroquinone controversy. *Dermatol Ther*. 2007;20:308–313.
4. Torok HM, Jones T, Rich P, et al. Hydroquinone 4%, tretinoin 0.05%, fluocinolone acetonide 0.01%: a safe and efficacious 12-month treatment for melasma. *Cutis*. 2005;75:57–62.
5. Dorsey CS. Dermatitic and pigmentary reactions to monobenzyl ether of hydroquinone: report of two cases. *Arch Dermatol*. 1960;81:245–248.
6. Price VH. Treatment of hair loss. *N Engl J Med*. 1999;341:964–973.
7. Messenger AG, Rundegren J. Minoxidil: mechanisms of action on hair growth. *Br J Dermatol*. 2004;150:186–194.
8. Smith S, Fagien S, Whitcup SM, et al. Eyelash growth in subjects treated with bimatoprost: a multicenter, randomized, double-masked, vehicle-controlled, parallel-group study. *J Am Acad Dermatol*. 2012;66:801–806.
9. Yoelin S, Walt JG, Earl M. Safety, effectiveness, and subjective experience with topical bimatoprost 0.03% for eyelash growth. *Dermatol Surg*. 2010;36:638–649.
10. Tosti A, Pazzaglia M, Voudouris S, Tosti G. Hypertrichosis of the eyelashes caused by bimatoprost. *J Am Acad Dermatol*. 2004;51:S149–S150.
11. Schweiger ES, Pinchover L, Bernstein RM. Topical bimatoprost for the treatment of eyebrow hypotrichosis. *J Drugs Dermatol*. 2012;11:106–108.
12. Beer KR, Julius H, Dunn M, Wilson F. Treatment of eyebrow hypotrichosis using bimatoprost: a randomized, double-blind, vehicle-controlled pilot study. *Dermatol Surg*. 2013;39:1079–1087.
13. Cohen JL. Enhancing the growth of natural eyelashes: the mechanism of bimatoprost-induced eyelash growth. *Dermatol Surg*. 2010;36:1361–1371.
14. Wolf Jr JE, Shander D, Huber F, et al. Randomized, double-blind clinical evaluation of the efficacy and safety of topical eflornithine HCl 13.9% cream in the treatment of women with facial hair. *Int J Dermatol*. 2007;46:94–98.
15. Hamzavi I, Tan E, Shapiro J, Lui H. A randomized bilateral vehicle-controlled study of eflornithine cream combined with laser treatment versus laser treatment alone for facial hirsutism in women. *J Am Acad Dermatol*. 2007;57:54–59.
16. Centers for Disease Control and Prevention, Workowski KA, Berman SM. Sexually transmitted diseases treatment guidelines, 2006. *MMWR Recomm Rep*. 2006;55:1–94.
17. Hadley G, Derry S, Moore RA. Imiquimod for actinic keratosis: systematic review and meta-analysis. *J Invest Dermatol*. 2006;126:1251–1255.
18. Swanson N, Abramovits W, Berman B, et al. Imiquimod 2.5% and 3.75% for the treatment of actinic keratoses: results of two placebo-controlled studies of daily application to the face and balding scalp for two 2-week cycles. *J Am Acad Dermatol*. 2010;62:582–590.
19. Ceilley RI, Del Rosso JQ. Current modalities and new advances in the treatment of basal cell carcinoma. *Int J Dermatol*. 2006;45:489–498.
20. Weisshaar E, Gollnick H. Potentiating effect of imiquimod in the treatment of verrucae vulgares in immunocompromised patients. *Acta Derm Venereol*. 2000;80:306–307.

Downloaded for Anonymous User (n/a) at Egyptian Knowledge Bank from ClinicalKey.com by Elsevier on March 10, 2024. For personal use only. No other uses without permission. Copyright ©2024. Elsevier Inc. All rights reserved.

21. Patel GK, Goodwin R, Chawla M, et al. Imiquimod 5% cream monotherapy for cutaneous squamous cell carcinoma in situ (Bowen's disease): a randomized, double-blind, placebo-controlled trial. *J Am Acad Dermatol*. 2006;54:1025–1032.
22. Berman B, Kaufman J. Pilot study of the effect of postoperative imiquimod 5% cream on the recurrence rate of excised keloids. *J Am Acad Dermatol*. 2002;47:S209–S211.
23. Cacao FM, Tanaka V, Messina MC. Failure of imiquimod 5% cream to prevent recurrence of surgically excised trunk keloids. *Dermatol Surg*. 2009;35:629–633.
24. Berman B, Harrison-Balestra C, Perez OA, et al. Treatment of keloid scars post-shave excision with imiquimod 5% cream: a prospective, double-blind, placebo-controlled pilot study. *J Drugs Dermatol*. 2009;8:455–458.
25. Katz KA. Imiquimod is not an effective drug for molluscum contagiosum. *Lancet Infect Dis*. 2014;14:372–373.
26. Desai T, Chen CL, Desai A, Kirby W. Basic pharmacology of topical imiquimod, 5-fluorouracil, and diclofenac for the dermatologic surgeon. *Dermatol Surg*. 2012;38:97–103.
27. Imbertson LM, Beaurline JM, Couture AM, et al. Cytokine induction in hairless mouse and rat skin after topical application of the immune response modifiers imiquimod and S-28463. *J Invest Dermatol*. 1998;110:734–739.
28. Vaccaro M, Barbuzza O, Guarneri B. Erosive pustular dermatosis of the scalp following treatment with topical imiquimod for actinic keratosis. *Arch Dermatol*. 2009;145:1340–1341.
29. Eichenfield LF, Tom WL, Berger TG, et al. Guidelines of care for the management of atopic dermatitis: section 2. Management and treatment of atopic dermatitis with topical therapies. *J Am Acad Dermatol*. 2014;71:116–132.
30. Carroll CL, Fleischer AB. Jr. Tacrolimus ointment: the treatment of atopic dermatitis and other inflammatory cutaneous disease. *Expert Opin Pharmacother*. 2004;5:2127–2137.
31. Callen J, Chamlin S, Eichenfield LF, et al. A systematic review of the safety of topical therapies for atopic dermatitis. *Br J Dermatol*. 2007;156:203–221.
32. Tennis P, Gelfand JM, Rothman KJ. Evaluation of cancer risk related to atopic dermatitis and use of topical calcineurin inhibitors. *Br J Dermatol*. 2011;165:465–473.
33. Luger T, Boguniewicz M, Carr W, et al. Pimecrolimus in atopic dermatitis: consensus on safety and the need to allow use in infants. *Pediatr Allergy Immunol*. 2015;26:306–315.
34. Legendre L, Barnetche T, Mazereeuw-Hautier J, et al. Risk of lymphoma in patients with atopic dermatitis and the role of topical treatment: a systematic review and meta-analysis. *J Am Acad Dermatol*. 2015;72:992–1002.
35. Thomson MA, Hamburger J, Stewart DG, Lewis HM. Treatment of erosive oral lichen planus with topical tacrolimus. *J Dermatolog Treat*. 2004;15:308–314.
36. Remitz A, Reitamo S. Long-term safety of tacrolimus ointment in atopic dermatitis. *Expert Opin Drug Saf*. 2009;8:501–506.
37. Yan AC, Honig PJ, Ming ME, et al. The safety and efficacy of pimecrolimus, 1%, cream for the treatment of Netherton syndrome: results from an exploratory study. *Arch Dermatol*. 2010;146:57–62.
38. Damsky W, King BA. JAK inhibitors in dermatology: the promise of a new drug class. *J Am Acad Dermatol*. 2017;76:736–744.
39. Papp K, Szepietowski JC, Kircik L, et al. Efficacy and safety of ruxolitinib cream for the treatment of atopic dermatitis: results from 2 phase 3, randomized, double-blind studies. *J Am Acad Dermatol*. 2021;85:863–872.
40. Rosmarin D, Passeron T, Pandya AG, et al. Two Phase 3, randomized, controlled trials of ruxolitinib cream for vitiligo. *N Engl J Med*. 2022;387:1445–1455.
41. Nakagawa H, Nemoto O, Igarashi A, et al. Delgocitinib ointment, a topical Janus kinase inhibitor, in adult patients with moderate to severe atopic dermatitis: a phase 3, randomized, double-blind, vehicle-controlled study and an open-label, long-term extension study. *J Am Acad Dermatol*. 2020;82:823–831.
42. Bissonnette R, Papp KA, Poulin Y, et al. Topical tofacitinib for atopic dermatitis: a phase IIa randomized trial. *Br J Dermatol*. 2016;175:902–911.
43. Liu LY, Craiglow BG, King BA. Tofacitinib 2% ointment, a topical Janus kinase inhibitor, for the treatment of alopecia areata: a pilot study of 10 patients. *J Am Acad Dermatol*. 2018;78:403–404.
44. Papp KA, Bissonnette R, Gooderham M, et al. Treatment of plaque psoriasis with an ointment formulation of the Janus kinase inhibitor, tofacitinib: a Phase 2b randomized clinical trial. *BMC Dermatol*. 2016;16:15.
45. Bayart CB, DeNiro KL, Brichta L, et al. Topical Janus kinase inhibitors for the treatment of pediatric alopecia areata. *J Am Acad Dermatol*. 2017;77:167–170.
46. Worm M, Bauer A, Elsner P, Mahler V, Molin S, Nielsen TSS. Efficacy and safety of topical delgocitinib in patients with chronic hand eczema: data from a randomized, double-blind, vehicle-controlled phase IIa study. *Br J Dermatol*. 2020;182:1103–1110.
47. Paller AS, Tom WL, Lebwohl MG, et al. Efficacy and safety of crisaborole ointment, a novel, nonsteroidal phosphodiesterase 4 (PDE4) inhibitor for the topical treatment of atopic dermatitis (AD) in children and adults. *J Am Acad Dermatol*. 2016;75:494–503.e4.
48. Lebwohl MG, Kircik LH, Moore AY, et al. Effect of roflumilast cream vs vehicle cream on chronic plaque psoriasis: the DERMIS-1 and DERMIS-2 randomized clinical trials. *JAMA*. 2022;328:1073–1084.
49. Lebwohl MG, Stein Gold L, et al. Phase 3 trials of tapinarof cream for plaque psoriasis. *N Engl J Med*. 2021;385:2219–2229.
50. Longley DB, Harkin DP, Johnston PG. 5-fluorouracil: mechanisms of action and clinical strategies. *Nat Rev Cancer*. 2003;3:330–338.
51. Tsai EY, Zackheim H, Kim YH. Topical and intralesional chemotherapeutic agents. In: Wolverton SE, ed. *Comprehensive Dermatologic Drug Therapy*. 2nd ed. Philadelphia: Saunders; 2007.
52. Jansen MHE, Kessels JPHM, Nelemans PJ, et al. Randomized trial of four treatment approaches for actinic keratosis. *N Engl J Med*. 2019;380:935–946.
53. Sachs DL, Kang S, Hammerberg C, et al. Topical fluorouracil for actinic keratoses and photoaging: a clinical and molecular analysis. *Arch Dermatol*. 2009;145:659–666.
54. Cunningham TJ, Tabacchi M, Eliane JP, et al. Randomized trial of calcipotriol combined with 5-fluorouracil for skin cancer precursor immunotherapy. *J Clin Invest*. 2017;127:106–116.
55. Talpur R, Venkatarajan S, Duvic M. Mechlorethamine gel for the topical treatment of stage IA and IB mycosis fungoides-type cutaneous T-cell lymphoma. *Expert Rev Clin Pharmacol*. 2014;7:591–597.
56. Berthelot C, Rivera A, Duvic M. Skin directed therapy for mycosis fungoides: a review. *J Drugs Dermatol*. 2008;7:655–666.
57. Lessin SR, Duvic M, Guitart J, et al. Topical chemotherapy in cutaneous T-cell lymphoma: positive results of a randomized, controlled, multicenter trial testing the efficacy and safety of a novel mechlorethamine, 0.02%, gel in mycosis fungoides. *JAMA Dermatol*. 2013;149:25–32.
58. Zackheim HS. Treatment of mycosis fungoides with topical nitrosourea compounds. *Arch Dermatol*. 1972;106:177–182.
59. Zackheim HS, Epstein Jr EH, Crain WR. Topical carmustine (BCNU) for cutaneous T cell lymphoma: a 15-year experience in 143 patients. *J Am Acad Dermatol*. 1990;22:802–810.
60. Zackheim HS, Feldmann RJ, Lindsay C, Maibach HI. Percutaneous absorption of 1,3-bis (2-chloroethyl)-l-nitrosourea (BCNU, carmustine) in mycosis fungoides. *Br J Dermatol*. 1977;97:65–67.
61. Helfrich YSD, Kang S. Topical vitamin D_3. In: Wolverton SE, ed. *Comprehensive Drug Therapy*. 2nd ed. Philadelphia: Saunders; 2007.
62. Ashcroft DM, Po AL, Williams HC, Griffiths CE. Systematic review of comparative efficacy and tolerability of calcipotriol in treating chronic plaque psoriasis. *BMJ*. 2000;320:963–967.
63. Lebwohl M, Siskin SB, Epinette W, et al. A multicenter trial of calcipotriene ointment and halobetasol ointment compared with either agent alone for the treatment of psoriasis. *J Am Acad Dermatol*. 1996;35:268–269.
64. Kircik L. Efficacy and safety of topical calcitriol 3 microg/g ointment, a new topical therapy for chronic plaque psoriasis. *J Drugs Dermatol*. 2009;8:s9–s16.
65. Lebwohl M, Menter A, Weiss J, et al. Calcitriol 3 microg/g ointment in the management of mild to moderate plaque type psoriasis: results from 2 placebo-controlled, multicenter, randomized double-blind, clinical studies. *J Drugs Dermatol*. 2007;6:428–435.
66. Veien NK, Bjerke JR, Rossmann-Ringdahl I, Jakobsen HB. Once daily treatment of psoriasis with tacalcitol compared with twice daily treatment with calcipotriol. A double-blind trial. *Br J Dermatol*. 1997;137:581–586.
67. Paghdal KV, Schwartz RA. Sirolimus (rapamycin): from the soil of Easter Island to a bright future. *J Am Acad Dermatol*. 2007;57:1046–1050.
68. Ormerod AD, Shah SA, Copeland P, et al. Treatment of psoriasis with topical sirolimus: preclinical development and a randomized, double-blind trial. *Br J Dermatol*. 2005;152:758–764.
69. Tu J, Foster RS, Bint LJ, Halbert AR. Topical rapamycin for angiofibromas in paediatric patients with tuberous sclerosis: follow up of a pilot study and promising future directions. *Australas J Dermatol*. 2014;55:63–69.
70. Haemel AK, O'Brian AL, Teng JM. Topical rapamycin: a novel approach to facial angiofibromas in tuberous sclerosis. *Arch Dermatol*. 2010;146:715–718.
71. Foster RS, Bint LJ, Halbert AR. Topical 0.1% rapamycin for angiofibromas in paediatric patients with tuberous sclerosis: a pilot study of four patients. *Australas J Dermatol*. 2012;53:52–56.
72. DeKlotz CM, Ogram AE, Singh S, et al. Dramatic improvement of facial angiofibromas in tuberous sclerosis with topical rapamycin: optimizing a treatment protocol. *Arch Dermatol*. 2011;147:1116–1117.
73. Mutizwa MM, Berk DR, Anadkat MJ. Treatment of facial angiofibromas with topical application of oral rapamycin solution (1mgmL(-1)) in two patients with tuberous sclerosis. *Br J Dermatol*. 2011;165:922–923.
74. Wataya-Kaneda M, Nakamura A, Tanaka M, et al. Efficacy and safety of topical sirolimus therapy for facial angiofibromas in the tuberous sclerosis complex: a randomized clinical trial. *JAMA Dermatol*. 2017;153:39–48.
75. Marqués L, Núñez-Córdoba JM, Aguado L, et al. Topical rapamycin combined with pulsed dye laser in the treatment of capillary vascular malformations in Sturge-Weber syndrome: phase II, randomized, double-blind, intraindividual placebo-controlled clinical trial. *J Am Acad Dermatol*. 2015;72:151–158.
76. Kurtyka DJ, Burke KT, DeKlotz CMC. Use of topical sirolimus (Rapamycin) for treating confluent and reticulated papillomatosis. *JAMA Dermatol*. 2021;157:121–123.
77. Coerdt KM, Todd SP, DeKlotz CMC. Topical rapamycin for acanthosis nigricans in the Fitzpatrick IV/V adolescent population. *Pediatr Dermatol*. 2021;38:296–298.
78. Anderson L, Schmieder GJ, Werschler WP, et al. Randomized, double-blind, double-dummy, vehicle-controlled study of ingenol mebutate gel 0.025% and 0.05% for actinic keratosis. *J Am Acad Dermatol*. 2009;60:934–943.
79. Ogbourne SM, Suhrbier A, Jones B, et al. Antitumor activity of 3-ingenyl angelate: plasma membrane and mitochondrial disruption and necrotic cell death. *Cancer Res*. 2004;64:2833–2839.
80. Berman B, Goldenberg G, Hanke CW, et al. Efficacy and safety of ingenol mebutate 0.015% gel after cryosurgery of actinic keratosis: 12-month results. *J Drugs Dermatol*. 2014;13:741–747.
81. Paghdal KV, Schwartz RA. Topical tar: back to the future. *J Am Acad Dermatol*. 2009;61:294–302.
82. Goeckerman WH. Treatment of psoriasis. Continued observations on the use of crude coal tar and ultraviolet light. *Arch Dermatol Syph*. 1931;24:446–450.
83. Harris DR. Old wine in new bottles: the revival of anthralin. *Cutis*. 1998;62:201–203.
84. Rivera A, Tyring SK. Therapy of cutaneous human Papillomavirus infections. *Dermatol Ther*. 2004;17:441–448.
85. Moed L, Shwayder TA, Chang MW. Cantharidin revisited: a blistering defense of an ancient medicine. *Arch Dermatol*. 2001;137:1357–1360.
86. Eichenfield LF, McFalda W, Brabec B, et al. Safety and efficacy of VP-102, a proprietary, drug-device combination product containing cantharidin, 0.7% (w/v), in children and adults with molluscum contagiosum: two phase 3 randomized clinical trials. *JAMA Dermatol*. 2020;156:1315–1323.
87. Gillbro JM, Olsson MJ. The melanogenesis and mechanisms of skin-lightening agents–existing and new approaches. *Int J Cosmet Sci*. 2011;33:210–221.
88. Roos TC, Alam M, Roos S, et al. Pharmacotherapy of ectoparasitic infections. *Drugs*. 2001;61:1067–1088.
89. Stuetz A, Baumann K, Grassberger M, et al. Discovery of topical calcineurin inhibitors and pharmacological profile of pimecrolimus. *Int Arch Allergy Immunol*. 2006;141:199–212.
90. Yosipovitch G, Maibach HI. Effect of topical pramoxine on experimentally induced pruritus in humans. *J Am Acad Dermatol*. 1997;37:278–280.
91. Young TA, Patel TS, Camacho F, et al. A pramoxine-based anti-itch lotion is more effective than a control lotion for the treatment of uremic pruritus in adult hemodialysis patients. *J Dermatolog Treat*. 2009;20:76–81.
92. McKemy DD, Neuhausser WM, Julius D. Identification of a cold receptor reveals a general role for TRP channels in thermosensation. *Nature*. 2002;416:52–58.
93. Peier AM, Moqrich A, Hergarden AC, et al. A TRP channel that senses cold stimuli and menthol. *Cell*. 2002;108:705–715.

Downloaded for Anonymous User (n/a) at Egyptian Knowledge Bank from ClinicalKey.com by Elsevier on March 10, 2024. For personal use only. No other uses without permission. Copyright ©2024. Elsevier Inc. All rights reserved.

94. Patel T, Ishiuji Y, Yosipovitch G. Menthol: a refreshing look at this ancient compound. *J Am Acad Dermatol*. 2007;57:873–878.
95. Lynn B. Capsaicin: actions on nociceptive C-fibres and therapeutic potential. *Pain*. 1990;41:61–69.
96. Caterina MJ, Schumacher MA, Tominaga M, et al. The capsaicin receptor: a heat-activated ion channel in the pain pathway. *Nature*. 1997;389:816–824.
97. Mason L, Moore RA, Derry S, et al. Systematic review of topical capsaicin for the treatment of chronic pain. *BMJ*. 2004;328:991.
98. Drake LA, Millikan LE. The antipruritic effect of 5% doxepin cream in patients with eczematous dermatitis Doxepin Study Group. *Arch Dermatol*. 1995;131:1403–1408.
99. Drake LA, Fallon JD, Sober A. Relief of pruritus in patients with atopic dermatitis after treatment with topical doxepin cream. The Doxepin Study Group. *J Am Acad Dermatol*. 1994;31:613–616.
100. Taylor JS, Praditsuwan P, Handel D, Kuffner G. Allergic contact dermatitis from doxepin cream. One-year patch test clinic experience. *Arch Dermatol*. 1996;132:515–518.
101. Loden M. Urea-containing moisturizers influence barrier properties of normal skin. *Arch Dermatol Res*. 1996;288:103–107.
102. Hellgren L, Larsson K. On the effect of urea on human epidermis. *Dermatologica*. 1974;149:289–293.
103. Hessel A, Cruz-Ramon JC. Agents used for treatment of hyperkeratosis. In: Wolverton SE, ed. *Comprehensive Drug Therapy*. 2nd ed. Philadelphia: Saunders; 2007.
104. Lin AN, Nakatsui T. Salicylic acid revisited. *Int J Dermatol*. 1998;37:335–342.
105. Imayama S, Ueda S, Isoda M. Histologic changes in the skin of hairless mice following peeling with salicylic acid. *Arch Dermatol*. 2000;136:1390–1395.
106. Van Scott EJ, Yu RJ. Hyperkeratinization, corneocyte cohesion, and alpha hydroxy acids. *J Am Acad Dermatol*. 1984;11:867–879.
107. Smith WP. Epidermal and dermal effects of topical lactic acid. *J Am Acad Dermatol*. 1996;35:388–391.
108. Van Scott EJ, Yu RJ. Control of keratinization with alpha-hydroxy acids and related compounds. I. Topical treatment of ichthyotic disorders. *Arch Dermatol*. 1974;110:586–590.

Downloaded for Anonymous User (n/a) at Egyptian Knowledge Bank from ClinicalKey.com by Elsevier on March 10, 2024. For personal use only. No other uses without permission. Copyright ©2024. Elsevier Inc. All rights reserved.

eFig. 129.1 An adult fingertip unit.

eFig. 129.4 Exuberant inflammatory reaction following topical application of imiquimod to a lentigo maligna (melanoma *in situ*). The site had been pretreated for two weeks with 0.1% tazarotene cream. *Courtesy Lauren Daman, MD.*

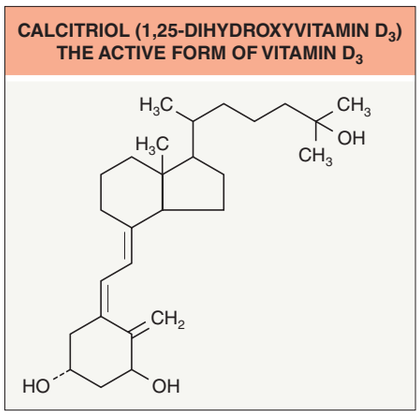

eFig. 129.2 Calcitriol (1,25-dihydroxyvitamin D_3), the active form of vitamin D_3.

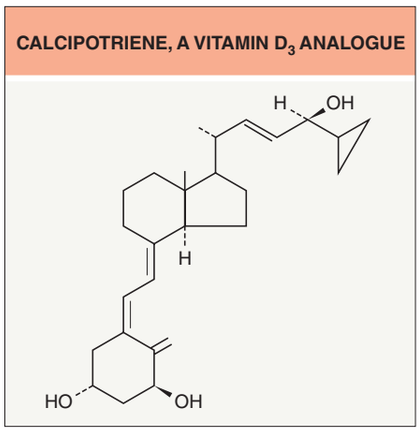

eFig. 129.3 Calcipotriene (calcipotriol), a vitamin D_3 analogue.

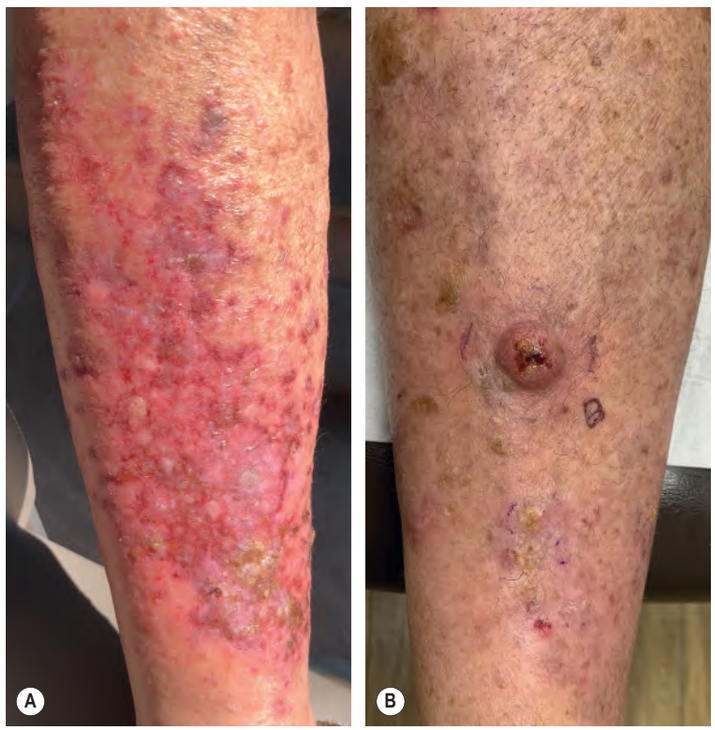

eFig. 129.5 Atypical squamous proliferations (ASPs) following topical imiquimod therapy. A Treatment of actinic keratoses on the shin of a woman with topical imiquimod (thrice weekly for three weeks) led to an exuberant inflammatory response that included eruptive ASPs. **B** While there was clearance of the inflammatory response and the majority of the ASPs after two weeks of topical corticosteroids, a KA-type of SCC developed requiring surgical removal. *Courtesy Karynne O. Duncan, MD.*

Downloaded for Anonymous User (n/a) at Egyptian Knowledge Bank from ClinicalKey.com by Elsevier on March 10, 2024. For personal use only. No other uses without permission. Copyright ©2024. Elsevier Inc. All rights reserved.

eFig. 129.6 Reactions to topical 5-fluorouracil. Note the erythema and crusting in areas of solar damage, as well as periorbital edema.

TRADITIONAL FDA CLASSIFICATION SYSTEM OF PHARMACEUTICAL PREGNANCY CATEGORIES	
Category	**Description**
A	Controlled studies show no risk. Adequate well-controlled studies in pregnant women have failed to demonstrate risk to the fetus.
B	No evidence of risk in humans. Either animal studies show risk, but human studies do not; or, if no adequate human studies have been done, animal findings are negative.
C	Risk cannot be ruled out. Human studies are lacking, and animal studies are either positive for fetal risk or lacking as well. However, potential benefits may justify the potential risk.
D	Positive evidence for risk. Human studies, or investigational or post-marketing data, show risk to fetus. Nevertheless, potential benefits may outweigh potential risk.
X	Contraindicated in pregnancy. Studies in animals or humans, or investigational or post-marketing reports, have shown fetal risk, which clearly outweighs any possible benefit to the patient.

eTable 129.1 Traditional FDA classification system of pharmaceutical pregnancy categories. In 2015, the FDA replaced these pregnancy risk categories with narrative sections addressing pregnancy and lactation, which include risk summaries as well as information on pregnancy exposure registries, clinical considerations, and available data. The new format is used for prescription drugs approved from June 30, 2015 onward and is being phased in for other drugs approved since 2001. FDA, Food and Drug Administration.

Downloaded for Anonymous User (n/a) at Egyptian Knowledge Bank from ClinicalKey.com by Elsevier on March 10, 2024. For personal use only. No other uses without permission. Copyright ©2024. Elsevier Inc. All rights reserved.